



UMEÅ UNIVERSITY

Malleus fracture

Experimental and clinical aspects

Anders Niklasson

Clinical Science, Otorhinolaryngology
Umeå 2019

Responsible publisher under Swedish law: the Dean of the Medical Faculty
This work is protected by the Swedish Copyright Legislation (Act 1960:729)
Dissertation for PhD

ISBN: 978-91-7855-021-0

ISSN: 0346-6612

New Series number 2013

Cover illustration: The first drawing of a malleus fracture, published by Dr Weir in 1870.

Electronic version available at: <http://umu.diva-portal.org/>

Printed by: Cityprint i Norr AB

Umeå, Sweden 2019

Contents

Abstract	iii
Abbreviations	v
Original papers	vi
Sammanfattning på svenska	vii
Introduction	1
History of the malleus fractures.....	1
Anatomy of the ear	2
Embryologi.....	4
Bone remodeling.....	4
Hearing physiology.....	6
Hearing loss	9
<i>Sensorineural hearing loss</i>	9
<i>Conductive hearing loss</i>	9
Diagnostic tools	9
<i>Microscopy and pneumatic otoscopy</i>	9
<i>Pure tone audiometry</i>	9
<i>Tympanometry</i>	10
Middle ear disease	11
<i>Chronic otitis media</i>	11
<i>Cholesteatoma</i>	11
<i>Otosclerosis</i>	12
Surgery of the ossicular chain	13
Experimental tools.....	15
<i>Laser Doppler vibrometry</i>	15
<i>Human temporal bones</i>	17
<i>Animal temporal bones</i>	18
<i>Micro-CT</i>	19
<i>Statistics</i>	19
Aims	20
Materials and Methods	21
Paper I.....	21
Paper II-III.....	21
Paper IV	25
Ethics approval	27
Results	28
Paper I.....	28
Paper II	30
Paper III	32
Paper IV	34

Discussion	35
Conclusion.....	41
Future perspectives	42
Acknowledgement.....	43
References	45

Abstract

Background

Patients with malleus fractures are described as rare in the literature. The cause of these fractures are most commonly trauma and digital manipulation of the ear canal, while in some cases the causes are unknown. At our clinic we record one new case every year, which leads to an incidence of approximately 40-50 new cases every year in Sweden. Different treatments have been proposed for this condition. However, since the condition is rare, no consensus has been reached regarding the best treatment. Additionally, it remains unclear whether malleus fractures can heal.

Aim

To get a deeper understanding of how malleus fractures occur, how they should be treated surgically, and if the malleus shows any sign of bone healing.

Materials and methods

Paper I. We carried out both a retrospective study of the medical records of nine Swedish patients with isolated malleus fractures, and a literature review of this condition. Symptoms, clinical findings and patients' history were collected.

Paper II. Ossiculoplasty on human temporal bones was performed in the presence of a malleus fracture. We developed a surgical model from freshly frozen human temporal bones, and we performed Laser Doppler vibrometry (LDV) measurements on this model both before and after ossiculoplasty.

Paper III. We performed ossiculoplasties with different types of partial ossicular replacement prostheses (PORP) on human temporal bones and we measured the results with LDV.

Paper IV. We performed an *in vivo* animal study on Merino sheep, in which we produced isolated malleus fractures. We then compared the bone healing of these fractures with that of the nasal bone and the mandible. Bone healing was detected with micro-CT.

Results

Paper I. The most common cause of isolated malleus fractures was found to be a so-called "digital" trauma, which occurred when the patients had removed a finger from the wet ear canal after bath. The hearing loss was occasionally accompanied by tinnitus and transient pain. Pneumatic otoscopy and tympanometry showed a hypermobile tympanic membrane, while audiometry showed a conductive hearing loss that increased towards higher frequencies.

Paper II. Our LDV measurements indicated that fixation of an isolated malleus with bone cement may give the best results after surgery.

Paper III. The best LDV measurements were obtained when ossiculoplasty was done using a PORP in lateral contact with both the tympanic membrane and the malleus handle.

Paper IV. In our animal study we found no signs of bone healing at micro-CT four weeks after producing the malleus fractures. In contrast, both the nasal bone and the mandible showed bone healing. This indicates that the bone healing properties of the ossicles probably differ from those of other bones in the body.

Conclusion

Digital trauma is the major cause of isolated malleus fractures. Pneumatic otoscopy and tympanometry showed a hypermobile tympanic membrane, while audiometry showed a conductive hearing loss increasing towards the higher frequencies. We developed a method to employ freshly frozen human temporal bones and we used LDV for detecting optimal results. This method allows to evaluate and develop otosurgery, aimed to restore hearing after an interrupted ossicular chain. The animal study indicates that malleus fractures will not heal spontaneously.

Abbreviations

AC	Air Conduction
BC	Bone Conduction
COM	Chronic Otitis Media
CHL	Conductive Hearing Loss
dB	decibel
Hz	Hertz
IMJ	Incudomalleal joint
ISJ	Incudostapedial joint
LDV	Laser Doppler Vibrometry
Micro-CT	Micro-Computed Tomography
PORP	Partial Ossicular Replacement Prosthesis
SD	Standard Deviation
SEM	Standard Error of the Mean
SNHL	Sensorineural Hearing Loss
TB	Temporal Bone
TM	Tympanic Membrane
TORP	Total Ossicular Replacement Prosthesis

Original papers

This thesis is based on the following papers.

- I. Niklasson A, Tano K. Self-inflicted negative pressure of the external ear canal: a common cause of isolated malleus fracture. *Acta Otolaryng.* 2010; 130:410–416.
- II. Niklasson A, Rönnblom A, Muyshondt P, Dirckx J, von Unge M, Tano K. Ossiculoplasty on isolated malleus fractures: a human temporal bone study using Laser Doppler vibrometry. *Otol Neurotol.* 2016; 37(7):895-901.
- III. Niklasson A, Gladiné K, Rönnblom A, von Unge M, Dirckx J, Tano K. An optimal partial ossicular prosthesis should connect both to the tympanic membrane and malleus. A temporal bone study using Laser Doppler vibrometry. *Otol Neurotol.* 2018; 39:333–339.
- IV. Niklasson A, Tano K, Dilley R, Pavlos N, Musk G, Atlas M, von Unge M. Malleus fracture healing studied in a new sheep model (Manuscript in preparation)

Reprints are made with permission from the publishers.

Sammanfattning på svenska

De flesta författare tycks vara eniga om att isolerad fraktur på hammarskaftet är en ovanlig diagnos, men kanske underdiagnostiserad. I modern litteratur finns cirka 50 fall beskrivna. På ÖNH-klinikerna i Norrbotten har vi dock under de senaste 10 åren hittat cirka 10 patienter med en isolerad hammarskaftsfraktur.

I det första delarbetet, en fallstudie, var målet att få en djupare förståelse för hur frakturer på hammarskaftet uppstår, diagnosticeras och behandlas. I detta delarbete framkom det att hammarskaftsfrakturer sannolikt är vanligare än man tidigare anat. Majoriteten av frakturerna har uppstått efter att patienterna dragit ut sitt blöta finger ur hörselgången efter dusch/bad. De har upplevt symptom i form av övergående smärta, ibland tinnitus och en bestående hörselnedsättning. För att kunna sätta diagnosen hammarfraktur har man god hjälp av hörselprov som visar ett ledningshinder med ökning mot diskantområdet och man ser också en överrörlig trumhinna vid Siegling och vid tympanometri. Oftast finner man även en veckbildning på trumhinnan nedanför spetsen på hammarskaftet. En medvetenhet hos undersökaren ger med riktad undersökning rätt diagnos. Olika typer av kirurgi är gjorda med lite varierande resultat.

Vi utvecklade en modell på färskfrysta humana temporalben för att undersöka hur hammarfrakturer kirurgiskt kan behandlas på bästa sätt. En försöksdesign skapades där innerörat togs bort och medialsidan av stigbygelplattan visualiserades för att kunna mäta dess vibrationer. En öppning gjordes via mellersta skallgropen in till mellanörat för att kunna göra olika typer av hörselbensplastik. Hörselbensplastik, eller ossiculoplastik, som det också kallas innebär att man i de flesta fall sätter en protes mellan trumhinnan och stigbygel för att överbrygga den eller de defekter som uppstått. Genom att skicka in ljudvågor mot trumhinnan och sen mäta vibrationerna på stigbygelplattan kunde vi mäta resultaten av de olika ingreppen som vi gjorde.

Vibrationer i stigbygeln mäts med Laser Doppler vibrometry (LDV). Detta är en metod där den så kallade Dopplereffekten utnyttjas. En sådan effekt kan upplevas då man som stillastående observatör hör ljudet av ett utryckningsfordon med siren passera. Ljudet ändrar då ton från en högre till en lägre då fordonet passerar. Ljudsignalen (frekvensen) pressas samman då den kommer mot observatören och en högre ton med hög frekvens hörs för att sedan sjunka med lägre ton och frekvens då det passerar. En laserstråle som är kopplad till ett mikroskop skickas mot det rörliga föremålet, i detta fall den vibrerande stigbygelplattan. En del av strålen reflekteras tillbaka och kan mätas. Eftersom plattan är i rörelse kommer frekvensen ändras beroende på hur plattan rör sig. När plattan rör sig bort från laserstrålen förlängs frekvensen och då plattan rör

sig mot laserstrålen kommer den att förkortas och en Dopplereffekt har uppstått. Hastigheten av stigbygelp Plattans vibrationer är direkt proportionerlig mot de ljudvågor som vi skickar in mot trumhinnan och kan därför översättas till skillnader i decibel.

I det andra delarbetet gjorde vi en hammarfraktur och testade olika metoder att överbrygga frakturen. Vi jämförde lagning av frakturen med cement och en specialdesignad hammarprotes med konventionell hörselbensplastik. En konventionell hörselbensplastik innebar i detta fall att städet togs ut, omformades och sattes tillbaka mellan stigbygeln och trumhinnan. Vi fann att lagning med cement fungerade bäst, även om de andra varianterna fungerade nästan lika bra.

Det är inte alltid möjligt att använda cement eller en hammarprotes för den delen. Spalten mellan frakturen kan tex vara för bred, den distala delen av hammaren kan ibland även saknas och det kan vara tekniskt svårt att få till en hammarprotes. Därför använder man ofta en konventionell hörselbensplastik där en protes sätts på stigbygeln och vilar utåt mot trumhinna och/eller hammarskaft. I tredje delarbetet jämförde vi olika varianter av en sådan hörselbensplastik där protesen satt på stigbygeln och hade olika kontakt med trumhinna och eller hammarskaftet. Vi fann att de proteser som hade kontakt med både trumhinna och hammarskaft hade bäst resultat i våra LDV-mätningar.

Det är tidigare känt att benet i både inneröra och hörselben är mycket hårda och att dessa ben i det närmaste är färdigutvecklade vid födseln. Man har även funnit en sämre läkningsförmåga jämfört med andra ben i kroppen. För att undersöka om det finns någon form av nybildning av ben i hörselbenen och ffa hammaren gjorde vi ett fjärde delarbete i en djurstudie där vi arbetade med får. Fårets öra är relativt likt ett mänskligt och tekniskt enklare att jobba med än andra djur i jämförbar storlek. Vi gjorde frakturer på hammaren och jämfördes dessa med frakturer på näsa och underkäke. Efter 4 veckor fann vi inga tecken på nybildning av ben i hammaren trots att dessa frakturer även kunde stabiliseras. Däremot såg vi nybildning av ben på frakturerna av näsa och underkäke.

Vi har kunnat visa att hammarfrakturer upptäcks oftare än vad som tidigare beskrivits om en medvetenhet finns om hur de uppkommer och hur de vanligtvis yttrar sig. Med hjälp av temporalben och laser har vi kunnat visa hur en hammarskaftsfraktur kan åtgärdas kirurgiskt och även kunnat studera olika parametrar för hur en protes skulle kunna vara beskaffad för att teoretiskt ge det bästa hörselresultatet. Vi har även sett att det inte tycks ske någon nybildning av ben i hammaren efter en fraktur. Detta är av betydelse då man väljer olika typer utav lagning. Vi såg tex att lagning med cement fungerar mycket bra. Det är däremot oklart om cementet är permanent stabilt över tid.

Introduction

History of malleus fractures

An isolated malleus handle fracture is rare according to the literature. Prosper Menière published in 1857 ¹ a case of a man that had a stick from a pear tree thrust into the ear. The malleus was described as broken, together with a ruptured tympanic membrane (TM). The injury healed spontaneously. In 1925, Drury ² presented an extensive review of 29 cases all described as fractures of the malleus handle. The causes were categorized into five groups (twigs entering the outer ear canal, foreign bodies, pen holders and hair pins, falls, and blows), and all of them presented additional lesions, including a ruptured TM. One of the cases in the abovementioned review was described in 1870 by Weir ³; in his paper, Weir published a drawing that, to the best of my knowledge, is the first one of a fractured malleus (Fig. 1). Weir reported that a man, Jeremiah Driscoll, had been unconscious after a fall outdoors, and suffered afterwards from hearing deficit and bleeding from his right ear. The TM was described as normal in color but, during inspection, an irregularity was found along the malleus handle and at the posterior part of the TM. The patient did not return for a follow-up.

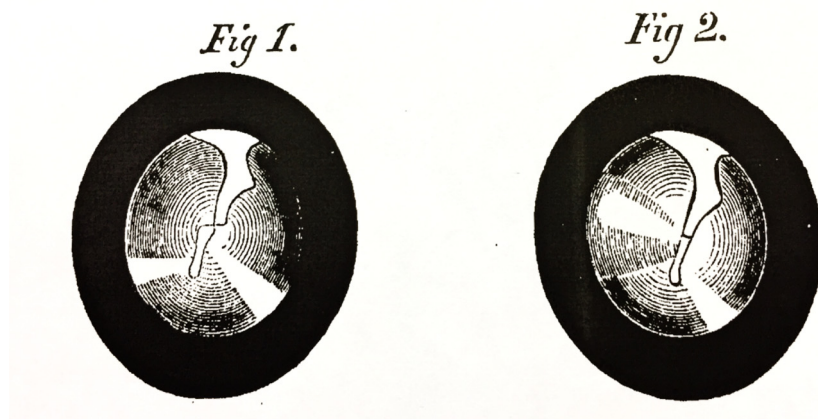


Figure 1. The first drawing of a fracture on the malleus handle. When performing Valsalva maneuver, the parts were well positioned, as shown in the original “Fig. 2”. Published in 1870. Permission to republish by The Laryngoscope.

After these historical findings, only one more case was published ⁴, until Harris and Butler ⁵ presented four cases of isolated malleus fracture in a paper from 1985. Three of these fractures were caused by different types of traumas to the ear, and one fracture had an unknown cause. One of the patients with a

barotrauma underwent exploratory tympanotomy due to a suspected perilymphatic fistula. The findings indicated the absence of a fistula, but instead a fracture of the malleus distal to the lateral process. A bone chip was wedged into the fracture site and resulted in postoperative hearing improvement. This was the first described attempt to restore the ossicular chain after a malleus fracture. In 1989, Pedersen ⁶ published the first report on isolated malleus fractures caused by rapidly removing a finger from the ear canal. Two patients had a malleus fracture with this same etiology and both were operated by wedging bone chips supported by Gelfoam® at the fracture site. Their hearing was described as restored after surgery.

Anatomy of the ear

The ear is divided in three parts: the outer, the middle and the inner ear. The outer ear consists of the auricle and the ear canal. The ear canal is about 2.5 cm long in adults and has a cartilaginous lateral part and a bony medial part. The conically formed TM constitutes the border between the outer ear and the middle ear. The middle ear is a gas-filled tympanic cavity containing the three ossicles (malleus, incus and stapes), their attaching muscle tendons and stabilizing ligaments, and the mastoid cells. The tensor tympany muscle originates from the eustachian tube and attaches with its tendon to the medial side of the malleus handle. The stapedius muscle arises from the pyramid process and attaches to the head of the stapes. The eustachian tube (or auditory tube) connects the tympanic cavity with the upper airway through an opening into the epifarynx (Fig. 2).

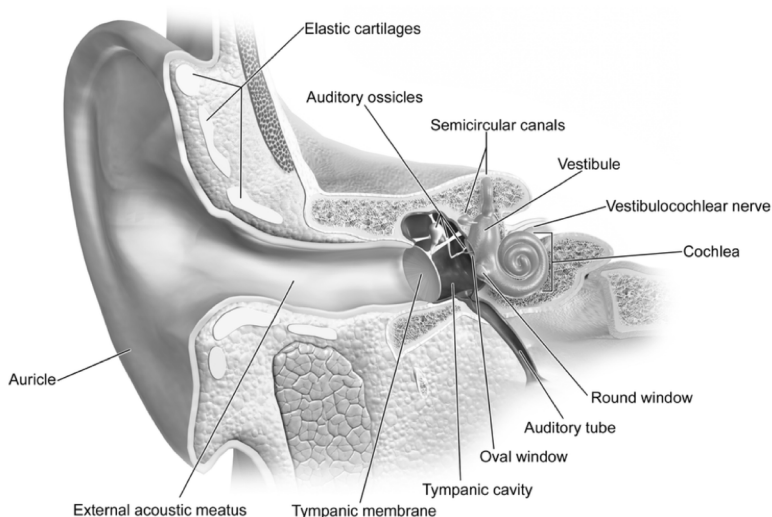


Figure 2. The anatomy of the outer, middle and inner ear. www.wikipedia.org, public access.

The malleus connects laterally, with its handle, to the TM, and medially, with its head, to the incus. Together with the stapes these three bones constitute the ossicular chain in the middle ear. The reason why humans have three ossicles is not clearly understood. Theories suggest that it could be a protective mechanism for the inner ear ^{7,8}. The ossicles are connected by two synovial joints: the incudomalleolar joint (IMJ) and the incudostapedial joint (ISJ). The long process of the incus ends with a thin bony pedicle, the lenticular process, connecting it to the ISJ ⁹. Whether in humans the annular ligament of the stapes plate is a synovial joint is not yet clear. However, a synovial lining has been found in some human specimens ¹⁰.

The arterial supply to the malleus and the incus derives from the anterior tympanic artery, which is the mandibular branch of the internal maxillary artery. It reaches the malleus and incus via ligaments ¹⁰ and mucosal folds ¹¹. The arterial supply to the stapes and the incudostapedial area derives from arteries in the stapedial tendon as well as from the posterior and anterior crural artery ¹⁰. Compared to other skeletal bones, relatively few blood vessels are found within the ossicles ¹². Nevertheless, these vessels are distributed rather uniformly in all three ossicles ¹³ and communicate with the abovementioned vessels (Fig. 3).

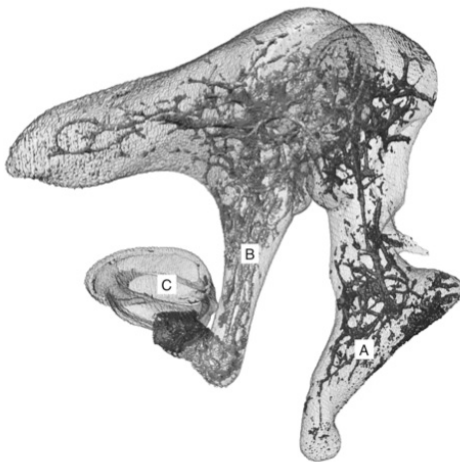


Figure 3. Micro-CT image showing an intertrabecular system within the ossicles that includes mostly blood vessels. A, malleus; B, incus; C, stapes. Reproduced from De Greef et al. ¹⁴. Permission to publish obtained by the publisher.

The inner ear consists of the cochlea, the vestibule and the vestibulocochlear nerve (Fig. 2). The cochlea is a bony labyrinth, the so-called otic capsule, located within the temporal bone (TB). It contains an inner membranous system that consists of three main parts (also called *scalae*): the vestibular, tympanic, and

medial *scala*. The vestibular and the tympanic *scalae* contain perilymph, and the medial *scala* contains endolymph. The medial *scala* is separated from the vestibular *scala* by the Reissner's membrane, and from the tympanic *scala* by the basilar membrane. The basilar membrane contains the organ of Corti, where the sensory hair cells are located.

Embryology

The malleus and incus originate from the first pharyngeal arch. After separation of the Meckel's cartilage, the malleus, incus and mandible are formed ¹⁵. Despite being of the same origin, the malleus and incus stop growing soon after birth ¹² and remain inert through life, whereas the mandible grows with the rest of the cranium. The mechanisms regulating this process are not yet clearly understood. The stapes originates from the second pharyngeal arch and is of dual origin. Most of its structure is from the neural crest as the malleus and incus, while the annular ligament originates from the mesoderm ¹⁶. The three ossicles are a feature unique to mammals, whereas birds and reptiles only have one ossicle, which is called columella or stapes ¹⁵. Findings obtained by studying fossils suggest that the malleus and incus are homologous (of the same embryonic origin) to, respectively, the so-called quadrate and the articular, which form the articulation for the upper and lower jaws in birds and reptiles ¹⁵. However, the development of the three ossicles occurs independently and in parallel, and not as an improved single-ossicle system ¹⁷. The evolution of the three-ossicle system plays an important role for hearing sounds of high frequencies ^{17,18}. Finally, the inner ear develops from two otic placodes ¹⁹, reaches its final size at gestational weeks 16-18, and the ossification is completed at the age of 2 years ²⁰.

Bone remodeling

In contrast to skeletal bone, which constantly undergoes remodeling due to mechanical load and non-mechanical factors such as hormones and cytokines, the ossicles in the middle ear and the surrounding otic capsule seem to be inert. Marotti et al. ¹² described in 1998 the distribution of dead osteocytes in human cadaver ossicles and compared it with osteocytes in the clavicle. The age of the cadavers studied ranged between 2 and 87 years. The amounts of dead osteocytes with empty *lacunae* were significantly higher in the ossicles than in the clavicle, thus defining a clear pattern. Also, the authors found that the number of dead osteocytes directly increased with age and distance from vessels. This phenomenon of osteocyte death in the ossicles appears soon after birth, since 40% of the osteocytes were already dead in the sample of a 2-year-old child. The authors proposed programmed apoptosis as a cause of this phenomenon, and also suggested that it might withstand remodeling forces that could otherwise alter the function of the ossicles. The hypothesis of programmed apoptosis in the

ossicles is supported by Palumbo et al. ²¹, who also stated that bone remodeling in *lacunae* with dead osteocytes would never occur.

The ossicles are almost entirely made up of compact bone ¹². By contrast, the otic capsule consists of three layers: an outer periosteal, a middle endochondral, and an inner endosteal layer. The middle endochondral layer is unique in its structure and contains calcified bone and calcified cartilage ²². In all other parts of the body this cartilage would be dissolved by phagocytosis, whereas it remains unaffected in the otic capsule. The function of this layer is unclear although probably important given its exceptional resistance to bone remodeling ²³.

Bone remodeling is scarce in the otic capsule ^{20,24} and similar patterns have been observed in the ossicles ^{12,21}. However, certain conditions, such as otosclerosis and Paget's disease show an increased bone remodeling in the otic capsule and the middle ear ²⁵. Pathologic remodeling may also occur during middle ear infections ²⁶.

The mechanism responsible for the normal and abnormal bone turnover has only been partially understood. A group of cytokines, including osteoprotegrin (OPG), probably play an important role in this process, as OPG inhibits bone remodeling. OPG is produced at high levels in the cochlea and is delivered through small channels within the bone ^{14,27,28}. It is not known whether the intertrabecular system (Fig. 3) within the ossicles has a similar role. However, studies conducted in mice have shown an increased bone resorption of the ossicles when lacking OPG ²⁹.

Hearing physiology

The middle ear ossicles work as an amplifier of sound so that airborne sound can penetrate the fluid-filled cochlea. The vibrations traveling from the larger TM (approx. 60 mm²) to the much smaller stapes plate (approx. 3 mm²), with a ratio of 20:1 ³⁰, represent the most important factor in this mechanism. Other important factors are the lever function, which gives an additional ratio of about 1.3:1 ³⁰, and the catenary (buckling) function, for which the conical shape of the TM about doubles the movement of the malleus ³¹. The product of these factors is $20 \times 1.3 \times 2 = 52$ (Fig 4). Consequently, the logarithmic conversion from sound pressure to decibel (dB, calculated as $20 \log 52 = 34$) indicates that the amplifying effect of the middle ear is in the vicinity of 34 dB.

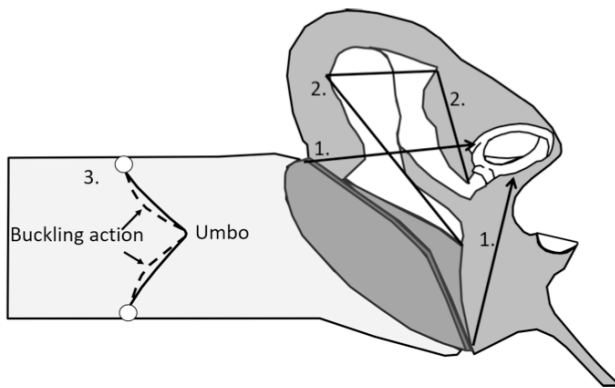


Figure 4. The middle ear increases sound pressure in three ways: 1. the TM is larger than the stapes foot plate (20:1); 2. the leverage action of the ossicles: the malleus is longer than the incus (1.3:1); 3) the buckling action of the TM (2:1). The product of these factors is 52, and $20 \log 52 = 34$ dB. Figure by Ted Venema PhD, modified and published with permission.

The acoustic function of the TM, which was thought of as a stiff membrane by Bekesy ⁸, has been later shown to be frequency-dependent. The pattern of the TM movements becomes more complex at higher frequencies ³¹. The studies by Bekesy ⁸ showed an immobile IMJ joint, but later studies have shown mobility of both the IMJ ³² and the ISJ ^{33,34}. The two joints in the middle ear could in this way act as a protective filter for the inner ear ³³. Although Elpern et al ³⁵ showed that fixation of IMJ or ISJ had very little effect on sound transmission, immobilization of the ISJ can cause a decrease of 5 dB ³⁶.

Regarding the vibration of the stapes in response to sound, a discussion is still ongoing on whether the movement is piston-like or has other more complex patterns. Bekesy described a hinge-like motion with a greater displacement at the anterior portion of the stapes ⁸. This is consistent with the anatomy of the ossicle,

having a thinner and wider annular ligament anteriorly than posteriorly ¹⁰. Bekesy also described a less efficient movement at higher sound pressure levels, where the stapes moved with a lengthwise rotation. These studies were made in TBs with a drained cochlea. Later studies demonstrated that in TBs with a drained cochlea the stapes has a more piston-like motion ³⁷, and stapes displacement was increased at high frequencies ³⁸. Vlaming and Feenstra ³⁹ described a piston-like movement at both low and high frequencies, but later studies showed a more complex movement at high frequencies. Heiland et al. ⁴⁰ reported a piston-like motion at up to 2,000 Hz, and a rocking movement around the long axis at higher frequencies (short axis was not measured). This notion is supported by reports by Voss et al. ⁴¹ and Hato et al. ³⁷, who found a primary piston-like motion respectively at up to 2,000 Hz ⁴¹ and 1,000 Hz ³⁷; after these frequencies the motion became more complex with rotatory movement around both the long and short axes.

The role of the two muscles in the middle ear (the tensor tympani and the stapedius) is not fully understood. The tensor tympani muscle is innervated by the trigeminal nerve. It reacts to self-generated noise, such as vocalization and swallowing, as well as to facial movements, but not to acoustic stimuli ⁴²⁻⁴⁴. The tensor tympani muscle reacts also when stimulating the orbital region with a blow of air ⁴³⁻⁴⁵, and has therefore been proposed as being part of a startle mechanism ⁴⁴. By this mechanism, the tensor tympani muscle can be an indirect protection from loud noises. The tensor tympani muscle reacts with greater latency than the stapedius muscle, but with longer duration ⁴⁶. The stapedius muscle is innervated by the facial nerve and reacts primarily to acoustic stimuli ⁴². Nonetheless, a stapelial reaction to electric cutaneous stimulation in the ear canal has also been described ⁴⁴. The stapedius contracts to low-frequency sounds (background noises) ⁴², thereby preserving the speech frequencies. However, the stapedius muscle shows a latency of contraction in response to acoustic stimuli. This is probably the reason why this muscle is not effective in case of impulsive noises ⁴⁷. The contractions of both muscles may also be of importance for the lubrication of the IMJ and ISJ ⁷.

Sound travels to the cochlea via two main pathways. The first, called air conduction (AC), is through the external ear canal, middle ear and then to the inner ear; the second, called bone conduction (BC), is through the cranial bone into the inner ear.

The BC pathway involves several routes: 1) compression of the cochlear bone, 2) middle ear ossicles inertia, 3) inertia of the cochlear fluid, 4) sound in the ear canal, and 5) pressure change in the cerebrospinal fluid ⁴⁸. The effect of BC on the cochlea can be massive at very high sound levels, such as explosions, but at

normal sound levels this effect is very small. Nevertheless, the BC pathway has been important in the development of bone-anchored hearing aids.

The AC pathway is divided in two routes before reaching the cochlea: the ossicular coupling and the acoustic coupling ⁴⁹. The ossicular coupling is the route via the TM and ossicular chain that, from vibrations on the stapes footplate, creates waves in the cochlea. The acoustic coupling is the route via the TM that reaches directly either the stapes or the round window (Fig. 5). In the normal ear the ossicular coupling is the dominating route, while the acoustic one is negligible ⁵⁰. Conversely, in reconstructed middle ears, or ears with discontinuity of the ossicular chain, the acoustic route plays a more important role ⁵⁰.

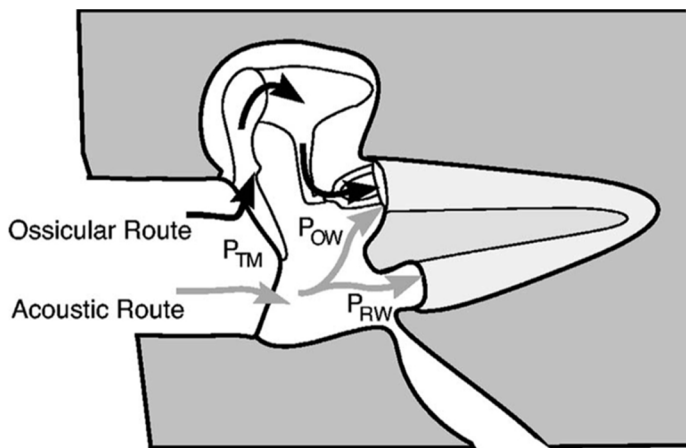


Figure 5. Schematic drawing of the two AC routes for sound transmission to the cochlea; the “ossicular” and “acoustic” routes. In the ossicular route, P_{TM} acts through the coupled motion of the TM, malleus, incus and stapes, and produces a pressure ($P_{ossicular}$) at the stapes footplate. In the acoustic route, P_{TM} produces a sound-pressure difference ($P_{OW} - P_{RW} = \Delta P_{WIN}$) between the oval and round windows. The net stimulus to the cochlea is the sum of the pressures transmitted via the two mechanisms: $P_{ossicular} + \Delta P_{win}$. Figure modified from Merchant et al. (1997b). Reproduced from Voss et al. ⁵¹, with permission to publish from the Acoustical Society of America.

The stapes movements in the oval window starts a wave in the vestibular *scala* that transfers to the tympanic *scala* and then to the round window, where an equal but opposite movement takes place. This wave affects the basilar membrane, thus mechanical wave impulses are transformed into nerve signals by both hair cells and the auditory nerve. This way, the signals are brought to the central nervous system.

Hearing loss

Sensorineural hearing loss (SNHL)

SNHL is a type of hearing loss that originates within the cochlea or the vestibulocochlear nerve. Different factors such as age, noise, infection, ototoxic drugs and inherited factors can contribute to SNHL. This deterioration can have a sudden onset, but most often increases with age and may be accompanied by tinnitus. An audiometry test is used to diagnose SNHL, and a hearing aid is the primary option if the patient desires a hearing improvement. Only for very severe cases of SNHL surgical management is considered an option. Surgery consists of a cochlear implant or, in case of dysfunction with the auditory nerve, a brain stem implant.

Conductive hearing loss (CHL)

CHL describes the loss of conduction of sound waves into the cochlea. Unlike SNHL, a CHL can often be treated surgically. A combination of both SNHL and CHL is referred to as mixed hearing loss. The origin of CHL can be anywhere from the outer ear to the stapes footplate. When the origin of CHL is in the ear canal, the cause can be as simple as ear wax, but also stenosis and, in rare cases, tumors. CHL caused by middle ear disease is summarized in the next chapter in “Middle ear disease”.

Diagnostic tools

Microscopy and pneumatic otoscopy

A microscope is used to get a clear view of the ear canal and the TM, which can then be examined in detail. Pneumatic otoscopy allows the examiner to evaluate the movement of the TM. An air-tight chamber with a lens and a cone is placed tight to the patient's external ear canal. The examiner can thus visualize the TM through the lens and, by gently blowing air in the ear canal, the TM will move accordingly.

Pure tone audiometry

To measure AC, an earphone is used and pure tones at frequencies from 250 to 8,000 Hz are presented. The lowest intensity (measured in dB) at which these pure tones are perceived 50% of the times is measured and is called “hearing threshold”.

Since the absolute values have a very large range, the intensity of sound (dB) is shown as a logarithmic scale: Sound pressure level (SPL) = $20 \log_{10}(\text{measured pressure}/\text{reference pressure})$ dB

Although any reference value may be used in the measurements of sound pressure, a standard reference level has been agreed upon. This so-called absolute

reference for sound pressure is the minimum detectible for humans, which is $20\mu\text{Pa}$.

The zero dB level has been calculated from a large number of hearing healthy young individuals; as a result, a normal hearing can differ from the zero dB level by -10 dB up to 20 dB, consequently, values ranging from -10 dB to 20 dB are considered as “normal hearing”.

To measure BC, an oscillator is placed on the mastoid and the threshold is measured. A normal AC means, in most cases, a normal hearing. On the other hand, BC gives a rough estimation of the cochlear function, thus if BC is better than AC a conductive hearing loss is suspected. If both the AC and BC curves show the same hearing loss, the patient suffers from a SNHL.

Tympanometry

Tympanometry is a test of the middle ear pressure, introduced by Terkildsen and Thomsen in 1959 ⁵², and indirectly tests the mobility of the TM. Tympanometry is performed with a probe that is placed tight in the external ear canal; at different pressures (+200 to -200 mmH₂O) a pure tone of 220 or 226 Hz is sent via the probe (Fig. 6). Since the TM will stiffen at lower and higher air pressures, the tone is measured at different pressure levels. The pure tone is reflected on the TM and recorded as a function of the different pressures. The values collected are then plotted in a graph called tympanogram.

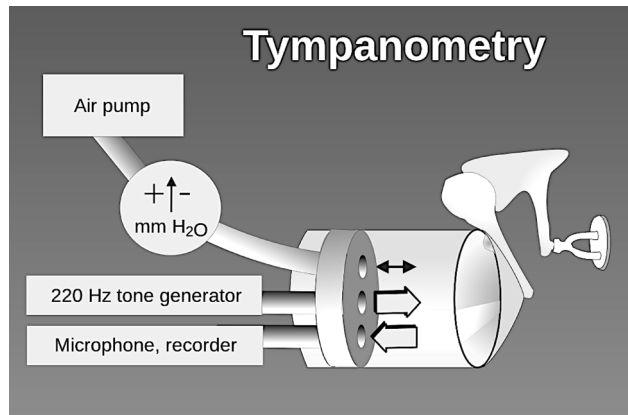


Figure 6. Schematic description of tympanometry. The ear canal is closed tight with a probe. A pure tone of 220 or 226 Hz at 70 dB is sent into the tympanic membrane (TM) and the pressure is regulated from 200 to -200 mmH₂O. From www.wikipedia.org, public access.

Although multi-frequency tympanometry has been tested with diagnostic advantages ⁵³⁻⁵⁵, the use of a low-frequency tone (220 or 226 Hz) is often preferred in the clinical setting. The vertical axis of the tympanogram shows the compliance, which is the inverse of the stiffness or resistance. The most efficient sound transmission occurs when the pressure on both sides of the TM is the same. In normal conditions, a tympanogram shows a so-called “type A” curve (Fig. 7). If the ossicular chain has been disarticulated, the stiffness of the TM decreases, and the curve on the tympanogram may have a higher or a double peak at zero air pressure (type Ad, Fig. 7). This pattern is evident in most of the cases of malleus fractures and is one of the main things to look for if a fracture is suspected.

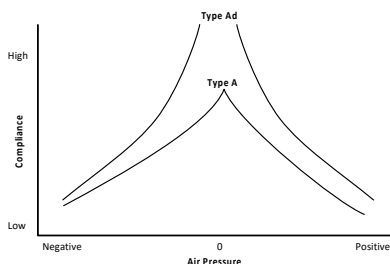


Figure 7. A normal type A tympanogram and a type Ad, showing a very high compliance. A type Ad curve is seen when the ossicular chain is disarticulated and is very common when a malleus fracture is present. Figure by Ted Venema PhD, modified and published with permission.

Middle ear disease

Chronic otitis media (COM)

COM is a chronic inflammation of the mucosa in the middle ear and mastoid. Retraction pockets with or without perforation of the TM are seen in COM. Examples of risk factors for developing COM are poor eustachian tube function, multiple acute otitis media episodes and different craniofacial abnormalities. Symptoms include persistent or intermittent painless otorrhea and hearing loss ⁵⁶. Erosion of the ossicles and especially of the long process of the incus is common ⁹. Local antibiotic or acidic drops and, occasionally, oral antibiotics can temporarily improve the otorrhea. In order to create a dry ear environment and improve hearing, surgery is usually needed. To this purpose, a myringoplasty, with or without ossiculoplasty, is normally performed. During a myringoplasty the perforated TM is patched with fascia, perichondrium or cartilage. During an ossiculoplasty the disrupted ossicular chain is reconstructed. The basic principles of ossiculoplasty will be described later.

Cholesteatoma

“Cholesteatoma is a mass formed by the keratinizing squamous epithelium in the tympanic cavity and/or mastoid and subepithelial connective tissue and by the progressive accumulation of keratin debris with/without a surrounding

inflammatory reaction”⁵⁷. The TM becomes invaginated in the middle ear while the lateral part of the TM, which is covered by keratinized epithelium, is trapped in a pouch; while the epithelium grows and desquamates, the pouch/cholesteatoma will also grow. Dysfunction of the eustachian tube and COM are risk factors for the development of a cholesteatoma⁵⁶, although the pathophysiology is not completely understood⁵⁷. The symptoms of cholesteatoma are otorrhea, hearing loss, and sometimes dizziness and facial palsy. Destruction of the ossicles is common and, as with COM, the most common site of destruction is the long process of the incus. The treatment of choice is surgery: ossiculoplasty and myringoplasty are sometimes combined with mastoidectomy in order to clear the mastoid from the desquamated epithelium.

Otosclerosis

Otosclerosis is an abnormal bony growth within the otic capsule, and involves especially the stapes⁵⁸. This condition may eventually lead to a stapes fixation and thus a CHL. In some cases, the otosclerosis also affects the inner ear, thus leading to a SNHL. The causes of otosclerosis are unknown. Hereditary factors and pregnancy were shown to be involved in its pathophysiology⁵⁹, although other authors did not find any correlation with pregnancy⁶⁰. Besides, infections such as measles could play a potential role; however, also in this case the results are diverging⁶¹.

A CHL loss often combined with a Carhart’s notch at 2,000 Hz is observed in otosclerosis⁶². The Carhart’s notch is a “false” dip in the BC at 2,000 Hz, which often disappears after stapedotomy. During stapedotomy a hole is made through the fixated stapes plate, in which a prosthesis is placed and then connected to the long process of the incus. This prosthesis will then replace the vibrations of the stapes plate. The Carhart’s notch is an indicator of otosclerosis, but is also present in many other middle ear pathologies, such as incudostapedial joint detachment, malleus or incus fixation⁶³ and secretory otitis media⁶⁴. It can also be observed in case of malleus fracture.

The causes of a Carhart’s notch are not clear. Possible factors contributing to a Carhart’s notch are the fact that BC has several pathways for sound transmission, and the resonance frequency of the ossicles. The resonance frequency of the ossicles has two modes: one for AC (800-1,200 Hz) and another for BC (1,500-2,000 Hz)⁶⁵. When the ossicular resonance/pathway is impaired and not contributing to sound transmission, a notch can be seen at this BC mode (2,000 Hz). Yet the Carhart’s notch can also be attributed to the increased impedance at the oval window⁶⁶.

Surgery of the ossicular chain

COM was a life-threatening disease in the past. Infection could lead to meningitis, brain abscesses and death. The discovery of penicillin in 1928 and its broader use in healthcare in the 1940s and 1950s dramatically reduced these complications. The use of penicillin, together with the pioneer work in the field of ear surgery by Horst Wullstein ⁶⁷ and Fritz Zollner ⁶⁸, led otosurgery from the simple removal of disease to the more complex reconstruction of the diseased ear. In the 1950s these surgeons developed methods for otosurgery that are still in use today and have been refined over the years.

The use of classification systems of tympanoplasty enables the evaluation and comparison among different techniques used. Briefly, type I includes only myringoplasty, in which the TM is repaired usually with temporalis fascia, perichondrium or cartilage. Type II includes the repair of the TM and restoration of a resorbed long process of the incus with bone graft, synthetic prostheses or bone cement. Type III includes the reconstruction of the ossicles with a partial ossicular replacement prosthesis (PORP) or a total ossicular replacement prosthesis (TORP) placed on the suprastructure or plate of a mobile stapes (Fig. 8). Types IV-V include extensive surgery due to more severe diseases: they often include mastoidectomy, eradication of the ossicles, and the restored TM resting on the stapes footplate. The focus in this thesis will be on ossiculoplasties of type II and III, while types I and IV-V will not be included here.

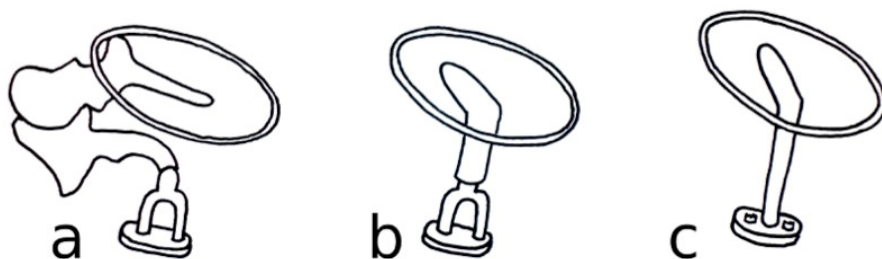


Figure 8. (a) Schematic picture of a normal middle ear with an intact ossicular chain. (b) PORP with its medial surface resting on the tip of stapes suprastructures. (c) TORP with its medial surface directly on the stapes plate. Figure by A. Rönblom.

Ossiculoplasty is usually performed using incus interposition: the incus is removed, reshaped and repositioned in the middle ear. Different materials have been used for ossiculoplasty, but none of them has been proven to be superior. Homographs (bone material from donors), autographs (ossicles, cortical bone and cartilage from the patient) and different materials, such as titanium, hydroxyapatite and plastic materials, have all been used clinically. Postoperative

hearing results depend not only on the level of experience of the surgeon, but also on technical factors such as stiffness of the material used, tension, weight and angle of the implanted prostheses. Moreover, the postoperative healing process can considerably affect sound transmission, thus making it difficult to discriminate whether the hearing results, good or bad, is due to the mechanical properties of the prosthesis or to the healing process.

The weight of the prosthesis can be 16 times the weight of the stapes (approx. 3 mg) and still have little reducing effect on the hearing results ⁶⁹. This conclusion is supported, although nuanced, by Nishihara and Goode ⁷⁰. In the latter study, stapes displacement deteriorated when 40 mg were added to the PORP. Additionally, according to their findings, two types of prostheses were proposed: one of about 15 mg for the best broad frequency response, and a lighter one for the best response at high frequency.

The importance of the tension of the prosthesis is also reported in many publications. A so-called “best fit” is often a loose coupling of the prostheses, which gives the best results in low and mid frequencies ⁷¹⁻⁷⁴. Other groups have also shown that a loose coupling gives the best results in the lower and mid frequencies, and that an increased stiffness deteriorates the low and improves the high frequencies ^{70,75,76}.

The angle at which the prosthesis is positioned from the stapes to the TM, with or without contact to the malleus, has also been investigated. Results show that an angle less than 45° seems to be favorable ^{70,71}.

Brackman et al. ⁷⁷ analyzed a series of 1,042 patients and reported a success rate of 73% (success was defined as less than 20 dB air-bone gap) for PORPs, and 55% for TORPs, when using Plasti-pore material. Similarly, Merchant et al. ⁷⁸ studied a series of 388 patients followed up postoperatively, and reported an air-bone gap of less than 20 dB in 82% using PORPs, and in 61% using TORPs. Also Colletti et al. ⁷⁹ reported results favoring PORPs versus TORPs in a series of 832 ossiculoplasties, and showed that hearing results deteriorated over a period of five years for both treatments. An important confounding factor that might affect the results is that the use of TORP might relate to a more severe disease in the middle ear. On the other hand, studies on TB ^{71,72,80} and at least one clinical study ⁸¹ show results that favor TORPs versus PORPs. Besides, it is almost impossible to perform clinical studies comparing all described variants of PORPs/TORPs as to evaluate the best one in terms of sound transmission ⁸². In the “Manual of middle ear surgery” by Tos ⁸³, the author describes more than 200 different variants of TORPs and PORPs.

Experimental tools

Laser Doppler vibrometry (LDV)

LDV is a non-contact optical technique for velocity measurements of vibrating objects. It is the non-contact nature of the measurements that makes it a valuable tool in the otologic field, where it allows repeated measurements without adding mass or stiffness to the system. These characteristics make LDV suitable for measuring, for example, vibrations in the middle ear.

Laser is an English acronym for Light Amplification by Stimulated Emission of Radiation. The light from the laser is monochromatic (one color) and coherent (same phase). The lasing material within the laser is stimulated by another energy source (usually an electrical current) to emit energy (photons); these photons are amplified by bouncing back and forth on mirrors on each side of the laser cavity and eventually leave the laser at one end, where it is partially transparent. In the studies presented in this thesis, a helium-neon laser with a wavelength of 0.6328 μm was used.

The Doppler effect was first described by the Austrian physicist Christian Doppler in 1842. It is a physical phenomenon that describes the change in wavelength and frequency of a wave when the observer and the source of sound are moving in relation to each other. The wavelength decreases when moving toward the observer and increases when moving away from the observer. This can be experienced also when emergency vehicles with sirens are approaching and passing: the frequency of the siren will decrease when passing. This is true for all kinds of waves; moreover, the Doppler effect, or shift as it also called, is present both when the waves move towards the observer and when the observer moves towards the waves. The same phenomenon happens when a laser light has a fixed wavelength and the object is moving. The wavelength of the laser light will be depressed or increased, according to the movement of the source.

The shift of frequencies that occur when the laser hits the moving or vibrating object can be measured because some of the backscattered light bounces back to a detector in the LDV-machine (Fig. 9). The vibrations can be measured according to the principles described above. The laser light is recorded by a detector and, after processing, an electrical signal is obtained. This electrical signal is directly proportional to the velocity of the vibrating object. The frequency of the backscattered light is very high and is not possible to measure; however, by letting the light interfere with another beam with slightly different wavelength, a so-called beat signal is obtained. This beat signal is lower in frequency but contains the same Doppler shift. The process is called heterodyne interferometry and is the basic method used in all LDVs. The beat signal can be measured and thus the direction of the vibrating object can be detected: if the beat signal is in

high frequency it means that the object has been moving towards the beam, whereas if the beat signal is in a lower frequency it means that the vibrating object has been moving away from the beam. A so-called Bragg cell is placed in the path of either the reference beam or the test beam. The Bragg cell modulates the frequency with a certain amount, usually 30-40 Hz, and enables the beat signal to become measurable in the MHz range.

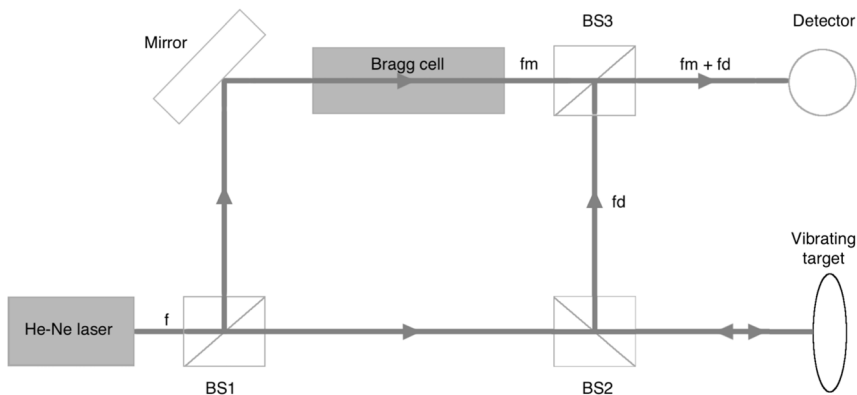


Figure 9. Schematic description of the LDV setup. The LDV detects the frequency shift from backscattered light, and the change in frequency is called the Doppler effect. To achieve this, a laser beam with known frequency (f) is split by a first beam splitter (BS1) into a reference beam and an illumination beam. The illumination beam passes a second beam splitter (BS2) and, when it is reflected from the vibrating object, its frequency is shifted because of the Doppler effect (f_d). The reference beam is frequency-modulated (f_m) by the Bragg cell. Both beams are recombined to a beat signal after passing a third beam splitter (BS3). The beat signal contains the same Doppler shift but, since it has lower frequency, it can be detected by the photo detector.

The LDV measurements in our experimental setting were used to analyze the velocity of the stapes movements. Since stapes velocity amplitudes are directly proportional to the hearing sensation, the dB values obtained by LDV can be interpreted as the hearing loss or gain in the same way as dB values are interpreted in an audiometry (Fig. 10 a and b). As with audiometry values, also the range of the velocity values is very wide; therefore, the measurements are converted to a logarithmic scale. By convention, the dB value is calculated with the formula $20 \log_{10}(\text{speed}/\text{reference speed})$. Our reference speed is 50 nm/s, which is a particle's velocity in air at 20 μPa (=threshold pressure of hearing in humans). The ratios of the dB in both audiometry and LDV are comparable, which indicates that improvements or deteriorations of the LDV measurements are a good indication of the efficiency of an ossiculoplasty on TBs.

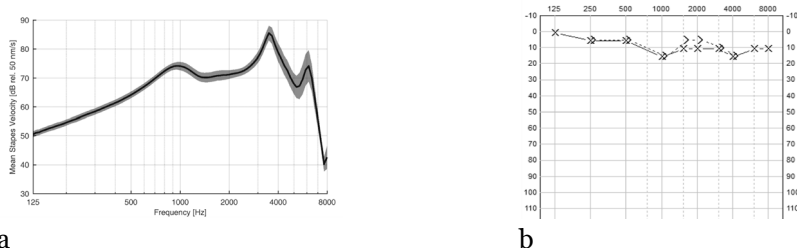


Figure 10. Examples of an LDV graph after measurements of stapes vibrations on TBs (n=5) with intact ossicular chain (a) and an audiogram showing normal hearing (b). The LDV is not an audiogram, yet the dB loss or gain correspond to the same loss or gain in an audiogram, since the stapes velocity is directly proportional to the hearing sensations. The shaded area in the LDV graph is the standard error of the mean.

Human TBs

The properties of freshly collected human TBs show the same dynamics in umbo velocity as those in living patients⁸⁴. The main limitations in their use are the difficulties of collecting fresh human bones and transporting them to the examiner. Therefore, human TBs that are kept frozen and then thawed before examination and measurements are mostly used. However, possible differences between fresh human TBs and freshly frozen TBs are still debated. Rosowski et al.⁸⁵ could not detect any significant difference when measuring the impedance in the middle ear on fresh and thawed TBs, as long as they were kept moist. Similarly, the authors did not find any difference in impedance, if the middle ear muscles (tensor tympany and stapedial tendon) were sectioned⁸⁵.

The lack of impact after sectioning the stapedial tendon has also been confirmed by another study⁸⁶; in the same paper, the authors also reported that drying the TBs could reduce the stapes velocity of up to 10 dB, especially below 1,000 Hz⁸⁶. Merchant et al.⁸⁷ also suggested similar changes in fresh TBs, compared to TBs

in living patients; however, the authors could not rule out post-mortem variations in the cochlea or the annular ligament when measuring stapes movements with an optical motion sensor.

Adding to this discussion, Ravicz et al. used the same technique with an optical sensor to measure stapes displacement ⁸⁸. The authors state the importance of using fresh TBs, due to the changes in the annular ligament and the risk of introducing air into the cochlea, both artifacts that could alter the results when measuring the stapes-cochlea impedance. Despite these contrasting observations and the difficulties in comparing results from studies conducted in different conditions, another study reported that thawed TBs show stable properties when repeatedly thawed and refrozen ⁸⁹. Also, these TBs showed no differences in LDV measurements with regard to the ossicles vibrations ⁸⁹.

Another concern when measuring stapes displacement regards the draining of cochlear fluid in TBs. Lord et al. ⁹⁰ reported only a slight difference in the stapes displacement when the cochlea was drained, when measuring on thawed TBs with LDV. On the other hand, Hato et al. ³⁷ detected a shift in the stapes movement when measuring stapes displacement on fresh TBs. The authors observed a more piston-like movement if the cochlea was drained, and the loss of its more complex pattern with rocking and rotatory movements at higher frequencies.

In studies of the middle ear with human TBs, the access often used is that provided by the posterior-tympanotomy approach ^{41,91-93}. This opening gives access to the middle ear through the mastoid cavity; moreover, in the experimental setting, it can be widened by salvaging both the facial nerve and the chorda tympany. The advantage of this approach is that it is a well-known technique for many otosurgeons. The disadvantages are that the technique is time-consuming and that the LDV beam is measured from an angle. This angle is usually between 20° and 50° and, by dividing by the $\cos \theta$, the final value can be calculated. However, the uncorrected values are often used as velocity data, because the very small differences in dB (0,5-4 dB) it would give and the uncertainty of the angle ⁴¹. In the studies here presented a different approach will be described in the material and method section: the approach via the middle fossa into the middle ear.

Animal TBs

Many different animal models have been used for experimental purposes in the field of otology: rodents ⁹⁴, chinchillas ⁹⁵, gerbils ⁹⁶, guinea pigs ⁹⁷, rabbits ⁹⁸ and cats ⁹⁹. Larger animals, such as pigs, are not good candidates in the context of middle ear surgery ¹⁰⁰. This is due to the large differences in the inner and middle ear compared to humans, as well as to the anatomical difficulties getting access to the middle ear because of the large amount of fatty tissue overlying the mastoid. On the other hand, the sheep is a more suitable animal model, because the anatomy and histology are more similar to humans. In general, the size of the structures in a sheep ear are approx. 2/3 that of a human ^{101,102}. Also, the sheep ear shows several histological similarities with humans ¹⁰³ in many areas, such as the middle ear epithelium, the type of ossification and ossicles ¹⁰⁴. Previous studies have described the sheep as a good model for surgical training ^{105,106}, as well as for developing implantable hearing devices ^{100,107} and prostheses on the stapes footplate ¹⁰⁸. Also, they are a type of prey animals that are easily handled in an experimental situation, a condition that can be stressful for many other animals. Yet, only two otosurgical studies have been published on living sheep until now ^{104,108}.

Micro-CT

A micro-CT is an x-ray computed tomography that creates a 3D-model of the object to study. The prefix micro (μ) indicates the pixel size and the range of the measurements, which are in the micrometer level. This enables a great resolution when studying small objects. In our case, we wanted to study the middle ear ossicles of sheep, and three surrounding bone structures (see description below).

Statistics

We used the standard error of the mean (SEM), where $SEM = SD/\sqrt{n}$. SD= standard deviation, and n= number of measurements. According to its definition, the SEM is related to the SD. The SD estimates the variations, or spread, of the individual data from the population mean. A low SD indicates a set of data clustered tightly to the mean, while a high SD indicates data with a wider spread. The SEM is commonly used when there are multiple measurements, and it estimates how the samples mean variates from the population mean. In other words, the SD of the mean is called the SEM. Both give similar results in our set up, due to the small number of samples.

Aims

In this study we ask if malleus fractures might be more common than described before; to this aim, we explore their causes and clinical findings. We also investigate the best option for surgical treatment and whether a fractured malleus can heal spontaneously.

The aims of the studies included in this thesis are the following:

- Paper I. To get an understanding of the causes, symptoms and clinical findings of malleus fractures in patients.
- Paper II. To investigate different surgical treatment options for a malleus fracture.
- Paper III. To investigate how an optimal PORP should be formed.
- Paper IV. To develop an animal model to investigate the bone healing capabilities of malleus.

Materials and Methods

Paper I

Self-inflicted negative pressure of the external ear canal: a common cause of isolated malleus fracture

This is a case report in which nine patients with a malleus handle fracture were studied, together with a literature review on the subject. We used data from four patients treated at our hospital between 1998 and 2008; also, colleagues from the Swedish Society of Otolaryngologists were encouraged to send us reports on patients with diagnosed isolated malleus fractures, resulting in five more cases. The patients' history, age, gender, clinical findings, symptoms, etiology and different treatment options are discussed and evaluated.

Paper II + III

II. Ossiculoplasty on isolated malleus fractures: a human temporal bone study using Laser Doppler Vibrometry

III. An optimal partial ossicular prosthesis should connect both to the tympanic membrane and malleus: a temporal bone study using Laser Doppler Vibrometry

Freshly frozen human TBs were used for the study reported in paper II (n=15) and III (n=6). Samples were kept at -20°C, then thawed and used in the experiments. All TBs were prepared in the same manner: the medial surface of the stapes plate was exposed by sawing and drilling away the cochlea and bone. In order to get access to the middle ear and be able to carry out ossiculoplasties and other procedures without damaging the TM, we used a middle fossa-like approach. We therefore created a wide opening extending from the anterior ligament to the tubal opening and leaving approximately 1 mm of bone before the anulus (Fig. 11).

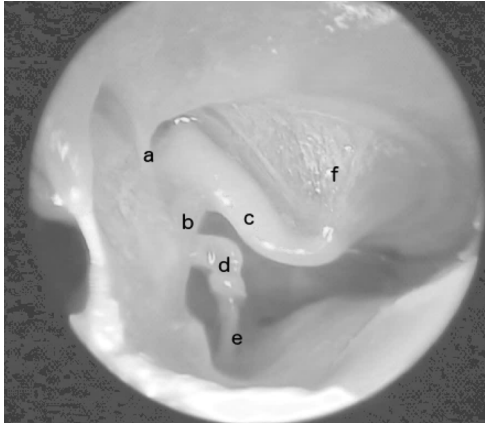


Figure 11. Photo of the drilled opening in the temporal bone (TB) and the access to the middle ear. The tympanic membrane (TM) and the ossicular chain are intact. a, anterior ligament; b, tensor tympani tendon; c, malleus handle; d, long process of incus; e, stapes; f, TM.

An earphone speaker and a microphone were screwed and sealed at the lateral opening of the bony ear canal (Fig. 12). We removed all soft tissue before attaching the speaker.

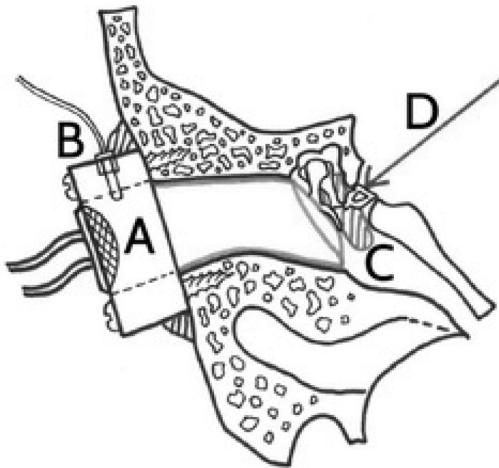


Figure 12. A schematic drawing of the LDV method used in the study. A, Speaker delivering controlled sound at different frequencies. B, Condenser microphone measuring the sound pressure level. C, Manipulation of the middle ear was made through a separate drilled hole from the side of the skull base. The tympanic membrane (TM) was intact throughout the experiment. D, LDV beam measuring the velocity of the vibrations of the medial side of the stapes footplate. Drawing by A. Rönnblom.

For each measured frequency the sound pressure was adjusted to 90 dB with an accuracy better than 1 dB. We chose the value of 90 dB because it produces the best quality and has a good signal-to-noise ratio. Instead, lower energy (dB) levels would produce a measurement with more noise. Vibrations from the stapes plate were measured with an LDV (Polytec model 534 and controller OFV-5000). The LDV was mounted on an operating microscope (Zeiss OPMI Sensera, Jena, Germany). The beam could be positioned with a joystick exactly on a reflective path (mass 0.04 mg, 0.4 x 0.4 mm) to the medial surface of the stapes plate.

Paper II

We fractured the malleus handle with backbiting forceps just distal to the insertion of the tensor tympany tendon. We then repaired the fractures using one of the following: bone cement (n=6), a PORP from cortical bone (n=5); or a malleus prosthesis from cortical bone (n=5) (Fig. 13).

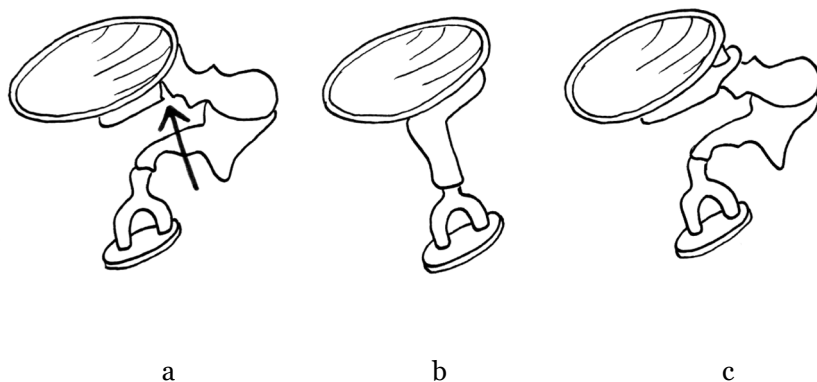


Figure 13. Schematic drawing of the three different ossiculoplasty that we performed. (a) Cement at the site of the fracture (arrow); (b) PORP in lateral contact with the tympanic membrane (TM). (c) Malleus prosthesis cemented in place on the lateral process of the malleus and the short stump left of the malleus after the distal part is extracted. Drawing by A. Rönblom.

We obtained the LDV measurements from the medial side of the stapes plate and we proceeded with their analysis. Besides comparing the results among the three types of ossiculoplasty, we also carried out three minor analyses using LDV data. Briefly, we analyzed the impact of the following factors: different localizations of the malleus fracture (n=1), dehydration of the TBs (n=2), and detachment of the TM from the malleus handle at different locations (n=3). In total, 15 TBs were used for repeated measurements (Table 1). Of these, 4 TBs were not included in the results (TB 1,2,3 and 5) due to technical issues at the start of the experiments.

TB (n=11)	Cement	Malleus prosthesis	PORP	Dehydrated	Different locations	Detachment
4	1		1			
7	1					
8	1					
9					1	
10		1				1
11	1	1	1			
12				1		1
A	1		1	1		
B	1	1				
D		1	1			
Control		1	1			1
Total	6	5	5	2	1	3

Table 1. Types of procedures and on which TB they were performed (n=11).

Paper III

The ability of different types of PORPs to recover stapes vibrations was compared both to the normal ossicular chain and among types of prostheses. The measurements with PORPs were always done at least two times and were adjusted for the best fit in each TB. The PORPs were chosen among the most common clinically used PORPs. The individual measurements of the eight different PORPs showed that they could be divided into three groups, according to their lateral contact: A) TMOs had lateral contact with the TM only (n=23); B) MSAs had lateral contact with the malleus handle only (n=10); and C) NiTa & Tubingen Hook had lateral contact with both the malleus handle and the TM (n=12) (Fig. 14). LDV measurements from the medial side of the stapes plate were obtained for analysis.

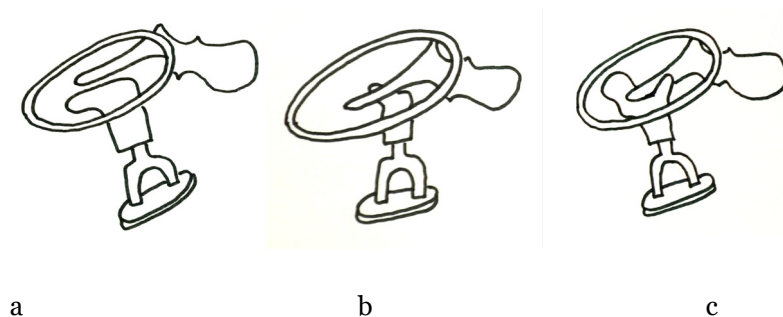


Figure 14. Schematic drawing of the types of PORPs used in the study: (a) TMO, lateral contact with the tympanic membrane (TM) only; (b) MSA, lateral contact with the malleus only; (c) NiTa & Tubingen Hook, lateral contact with both the malleus and the TM. Drawing by A. Rönnblom.

In each group we included different subtypes of prostheses, based on their different materials and different contact with the TM and the handle of the malleus (Table 2). Group A (n=4) includes Tubingen, Malleus head, PORP

posterior and PORP umbo; group B (n=2) includes MSA and MSA umbo; and group C (n=2) includes NiTa and Tubingen Hook. In an attempt to mimic a healed condition, four of the PORPs were fixed with glue at the end of the experiments. After gluing, however, the TB could not be used for further measurements.

Temporal Bone #	Group A				Group B		Group C	
	Tuebingen	Malleus head	PORP Posterior	PORP Umbo	MSA	MSA Umbo	NiTa	Tuebingen Hook
1	1	2 ^a	1	1	1	1	1	0
2	1	1	1	2 ^a	1	1	1	0
3	0	1	1	1	1 ^a	1	2	0
4	1	1	1	1	1	1	1	2
5	1	1	0	1	0	0	1	2
6	1	1	0	1	1	1	1 ^a	1
Total	5	7	4	7	5	5	7	5

Table 2. PORPs that were used for each temporal bone (TB) and the groups A, B and C according to their lateral contact. ^aGlued PORPs (n=4). After gluing, the TB was not used for further measurements. MSA, malleo-stapedial assembly; PORP, partial ossicular replacement prosthesis.

Paper IV

Malleus fracture healing studied in a new sheep model

One ear was operated in nine Merino sheep. The other ear was not operated both to be used as an untouched control and to maintain the hearing postoperatively. The sheep were acclimatized to the research facility for at least ten days prior to surgery in shared raised pens. Three days prior to surgery they were moved to individual raised pens. The ewes were 1-2 years of age and weighed on average 41.5 ± 3.0 kg. Pain and well-being were evaluated in the postoperative period twice daily for seven days, then once a day for other three weeks. All surgeries were done under general anesthesia and additional local anesthesia on the right side as to avoid excessive bleeding and limit pain after surgery. Four weeks after surgery the animals were euthanized with an intravenous injection of pentobarbitone and the fracture sites were harvested and processed for assessment.

For each sheep we performed one of the following malleus interventions: (a) fracture of the neck of the malleus; (b) fracture combined with the application of bone cement; and (c) a drilled hole in the malleus neck in order to simulate a completely stable fracture. As control interventions, fractures or bone chips were performed at the bony outer ear canal, nasal bone or mandible (Table 3).

Animal #	Malleus fracture	Malleus fracture +cement	Malleus drill hole	Ear canal fracture /drill hole	Nasal bone fracture	Mandible fracture /drill hole
1	+				+	
2			+	+/+		
3		+				+/+
4	+				+	
5			+	+/+		
6		+				+/+
7	+				+	
8			+	+/+		
9		+				+/+

Table 3. Study protocol for the surgery. The nine sheep were divided in three groups; in each group, surgery was performed at one site in the ear and at one specific site outside the ear (ear canal, nasal bone or mandible).

Tympanotomy

A retro-auricular semi-circular skin incision on the right side was made superiorly-posteriorly at approximately 3 cm from the insertion of the pinna to the skull. Due to a reaction of the Gudair vaccine prior to surgery¹⁰⁹ a lesion was found on this side in all but one sheep. This event slightly hindered the surgery, but did not change the established setting of operating the right side and saving the left one. We used the supra-mastoid process, which is the elongation of the zygomatic arc and the temporal crest of the mastoid bone (Fig. 15) as a landmark to the opening of the bony outer ear canal. We then identified and exposed the temporal muscle in the direction towards the bony meatus.

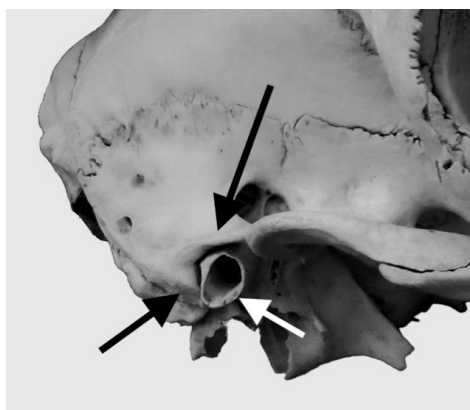

Figure 15. The supra-mastoid crest (long black arrow) and the temporal crest of the mastoid bone (short black arrow) were used as landmarks to the external ear canal (white arrow). Photo by Mike Tayler.

The bony meatus was exposed and widened posteriorly by drilling, in order to gain sufficient access to the middle ear. The posterior part of the bony ear canal and skin were lifted as was the *pars flaccida*. Thereby the region around the neck of the malleus, as well as the superior portion of the incus, could be visualized. After the interventions on the malleus, the tympano-meatal flap was put back in place and the medial portion of the external ear canal was filled with absorbable gelatin foam (Spongostan[®], Johnson & Johnson New Brunswick, New Jersey, U.S.A.) soaked in an ear surgery ointment containing antibiotics and cortisone (Terracortril with Polymyxin B[®], Pfizer Inc., New York, U.S.A.). Finally, the skin incision was sutured back in levels.

Fractures on the malleus were produced by cutting the neck of the malleus with backbiting forceps. Cement fixation was done using a surgical bone cement Oto-Mimix[®] (Olympus, Jacksonville, Florida, U.S.A.) application over the fracture and around the neck of the malleus. Drill holes were made with a 0.5 mm cutting burr.

The surgery at the control sites (the ear canal, nasal bone and the mandible) was performed with a chisel to create a 3-5 mm fracture/bone chip at each site; additionally, 0.5 mm drill holes were made in the mandible and the ear canal. After the sheep were euthanized, a portion of approximately 3 x 3 x 3 cm of the TB and the control sites were harvested using an oscillating saw. Portions of the mandible and the nasal bone were cut out for further assessment. The samples were put in formaldehyde for future analyses, including micro-CT and immunohistochemical analyses.

Ethics approval

All procedures involving the use of TBs in the studies were approved by the ethical committee of Umeå University, dnr 2014-352-31. All procedures involving the handling of the sheep were approved by AEC: R17/30779 (Western Australia).

Results

Paper I

Self-inflicted negative pressure of the external ear canal: a common cause of isolated malleus fracture

The main cause of malleus fractures is digital trauma (Fig. 16). In our study including nine patients, all except one had a clear history of this digital event at the time of hearing loss.

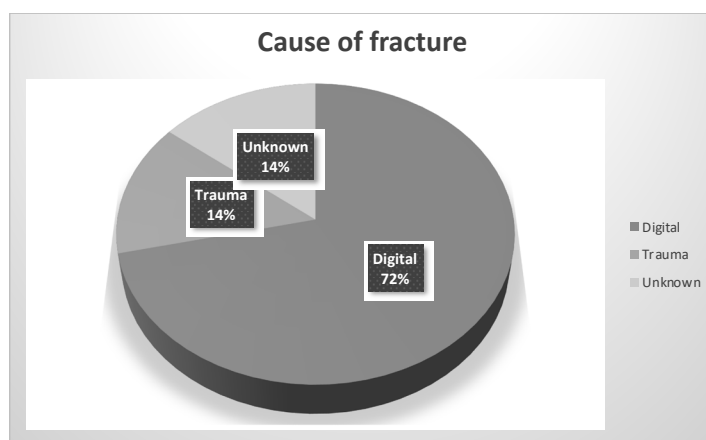


Figure 16. The etiology of isolated malleus fractures as reported in recent literature (n=28); 72% of the fractures were caused by digital manipulation of the external ear canal.

The patients usually suffered a sharp pain that spontaneously resolved after the manipulation; they also complained of a persisting mild hearing loss. Four of our nine patients (44,4%) suffered from tinnitus, which was not resolved after surgery. The mean age was 46 years (37-57 y) and the distribution of men/women was 3/6. No patient had any history of prior ear disease. Otomicroscopy showed a broken malleus with a wrinkled TM (Fig. 17); also, the use of pneumatic otoscopy was often helpful to detect hypermobility more easily.

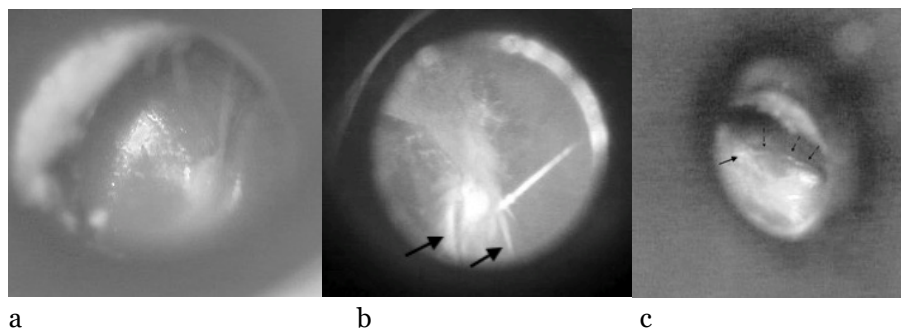


Figure 17. (a) Normal left-side tympanic membrane (TM) observed with a microscope. The picture shows the reflex of the TM in the anterior lower quadrant and a straight malleus handle. (b) A malleus fracture of the handle on the left side. Radiating wrinkles can be seen distal to the umbo (arrows). (c) Fracture on the right malleus handle with semicircle wrinkles (small dotted arrows) that in this case are anterior to the handle of the malleus. These wrinkles usually start at the fracture site (arrow).

A conductive hearing loss between 15-30 dB was detected with audiometry, and the air-bone gap usually increased from mid to high frequencies (Fig. 18 a). The lower frequencies were usually unaffected. A Carhart's notch was also detected in a few patients. All patients presented hypermobility at tympanometry, and the curve showed a high or a double-peak (Fig. 18 b).

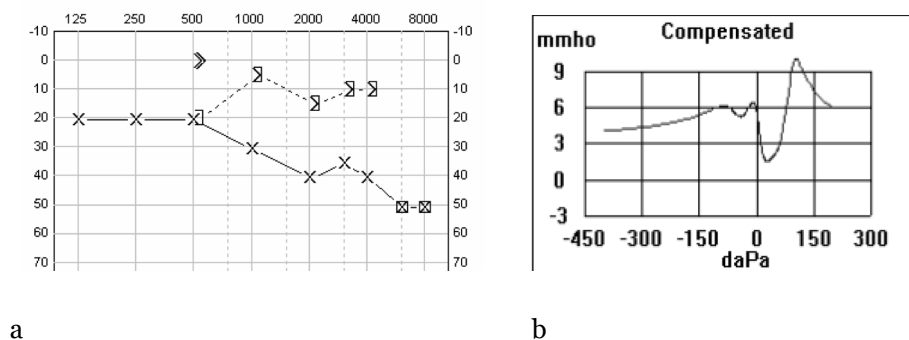


Figure 18. A typical audiometry (a) and tympanometry (b) patterns in the presence of a malleus fracture. The audiometry shows an increasing air-bone gap towards the high frequencies, and the tympanometry shows hypermobility.

The condition did not seem to heal spontaneously, therefore ossiculoplasty is a valuable option for those patients who want to improve their hearing. Among the cases presented in our review, about half were operated (16/28): two had exploratory surgery due to a suspected perilymphatic drainage, seven were operated with PORP or TORP, and seven with different types of ossicular chain conservative surgery in order to keep the ossicular chain intact (using cement, bone chips or cartilage). The audiometric outcome after surgery was not always

comparable due to missing audiometry data in some of the cases included in our review part. In addition, the postoperative BC data were also missing for some of our patients. Consequently, we could only compare the postoperative results from the hearing measured as AC (n=5). One year after surgery these five patients showed a mean improvement of 11.6 dB in AC.

Paper II

Ossiculoplasty on isolated malleus fractures: a human temporal bone study using Laser Doppler Vibrometry

LDV measurements obtained after repairing the fractures showed similar results in terms of improved sound transmission. This was true for all the three methods we used: bone cement applied directly at the site of the fracture (n=6), malleus prostheses (n=5), and PORPs (n=5). The PORPs showed a wider range of results, while the cement and the malleus prostheses had more predictable results. The bone cement group showed slightly better (5 dB) sound transmission in the mid frequencies (2,000 Hz) than the other two groups (Fig. 19).

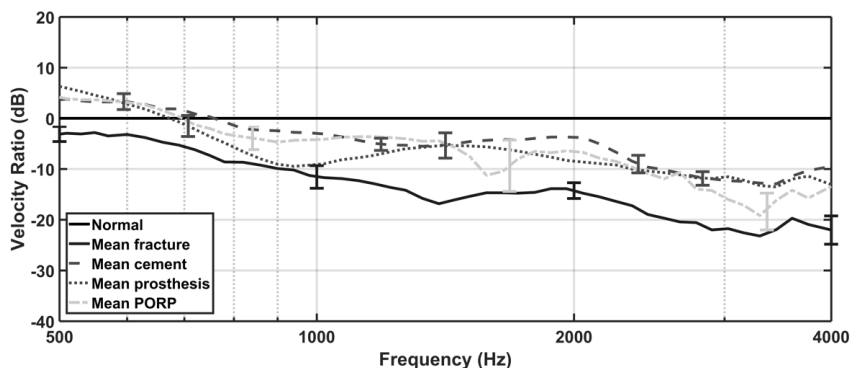


Figure 19. The mean LDV results of the three different types of ossiculoplasty. The sound transmission was similar in all three types. Fractures stabilized with cement showed slightly better (5 dB) results at 2000 Hz, compared to the regular cortical PORP and the malleus prostheses. Error bars indicate the SEM. The zero level depicts the sound transmission of the intact ossicular chain.

Furthermore, we found that the sound transmission deteriorated the more proximal the fracture was: for a distal fracture, a small loss of 5 dB was observed at 3,000 Hz, while for a proximal fracture a loss of 35 dB was observed at a maximum of 2,000 Hz. Dehydration caused a loss of velocity already within minutes, but rehydration after 21 hours restored the velocity.

Our data suggest that attachment of the TM to the whole length of the malleus was not extremely important: as long as both the lateral process and umbo were attached to the TM, sound transmission was only slightly affected (Fig. 20).

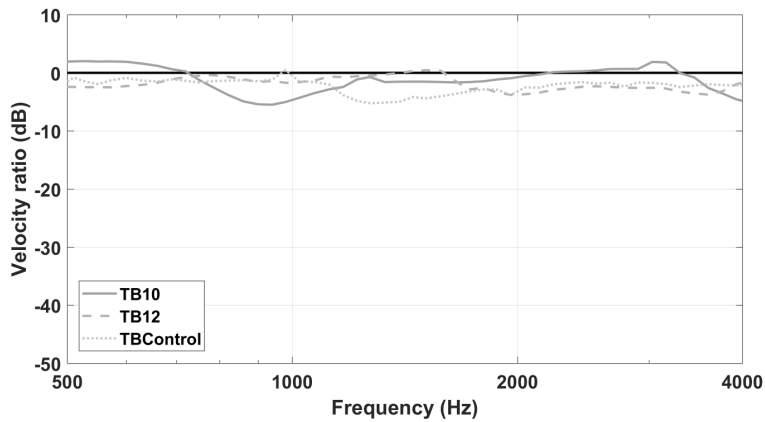


Figure 20. Three LDV measurements performed on malleus handle that is only attached with the lateral process and the umbo. The zero line depicts the results before the detachments were made. A loss between 0 and 5 dB is detected.

Paper III

An optimal partial ossicular prosthesis should connect both to the tympanic membrane and malleus: a temporal bone study using Laser Doppler Vibrometry

We found that the best sound transmission was obtained with prostheses that have contact both with the malleus handle and the TM (NiTa and Tübingen hook). This type of prostheses showed good results except at high frequencies, at which they still had better results than those of the other two groups. All three groups showed good sound transmission at low frequencies. The group with contact with the TM only (TMO) started to decrease after 1,000Hz, and the malleus handle only (MSA) after 2,000Hz (Fig. 21).

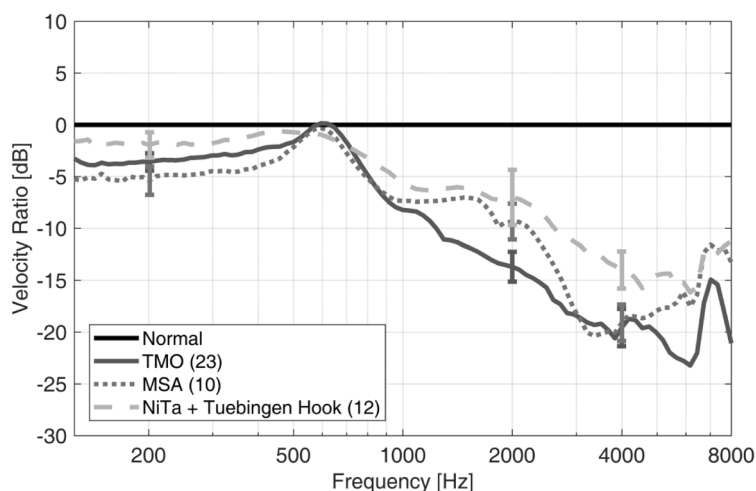


Figure 21. The three different groups of PORPs divided according to their lateral contact. NiTa and Tübingen showed a 5-10 dB increased sound transmission at the higher frequencies compared to the other two groups of PORPs.

In order to mimic the clinical conditions in which the PORPs become firmly attached to the TM and the stapes via fibrosis, we applied a small amount of glue. At first, glue was applied only to the malleus shaft and thereafter also to the stapes head. The results showed a better sound transmission at both low and high frequencies (Fig. 22).

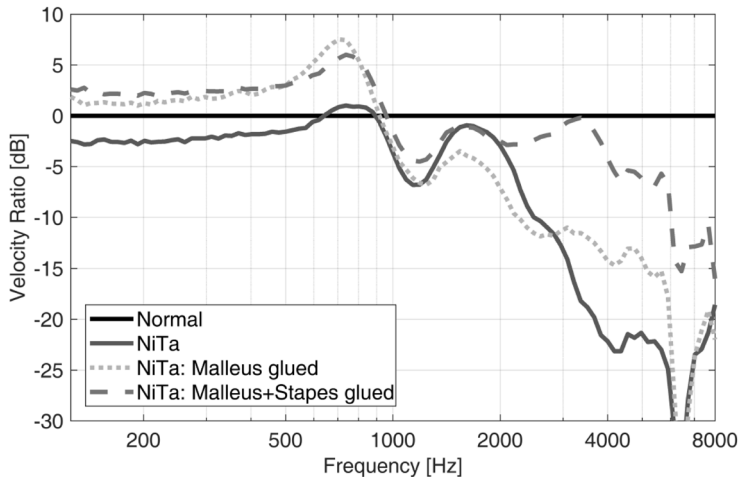


Figure 22. Glued NiTa showed an increased sound transmission especially at the higher frequencies.

Paper IV

Malleus fracture healing studied in a new sheep model

We found that the sheep withstood surgery well and showed well-being during the postoperative period. The sheep was found to be an excellent model for otological studies. The middle ear has a size allowing to perform various types of middle ear surgery, and portions of the ossicular chain are readily accessible after tympanotomy. The retro-auricular approach was feasible, although demanding because we needed to dissect more soft tissue than in humans before entering the ear canal. No evident signs of bone remodeling were observed in the malleus fractures (Fig. 23 a), in contrast to the control sites (mandible and nose) where bone remodeling was detected at micro-CT (Fig. 23 b, c). Micro-CT results from the ear canal are not yet available.

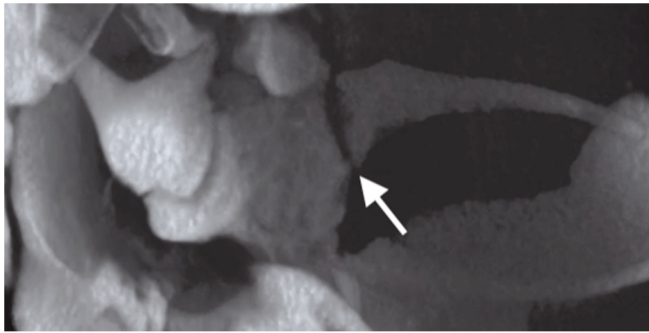
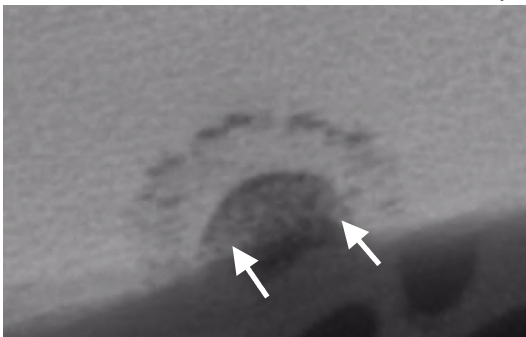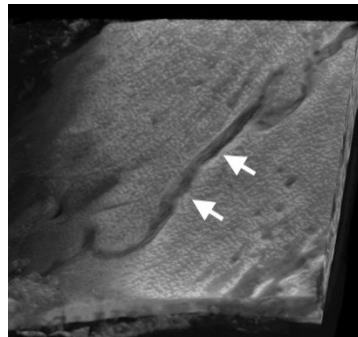


Figure 23 a. Fracture in the neck of the malleus (arrow) not showing any sign of bone remodeling after 4 weeks. This specific fracture was also stabilized using bone cement at the site of the fracture. The bone cement seems to have been resorbed or may be too thin to be detected at micro-CT.



b



c

Figure 23 b and c. A drill hole on the mandible (arrows). (b) A shadowing area at the edges of the drill hole can be seen as a sign of bone remodeling; (c) fracture of the nasal bone (arrows), where shadowing in the fracture space suggests bone remodeling.

Discussion

Paper I

Our results confirm that digital trauma is the main cause of isolated malleus handle fracture ¹¹⁰, as stated in the recent literature (1985-2017). In 1999, Iurato and Quaranta ¹¹¹ published an excellent review of forty-three cases, starting with the case reported by Menière in 1857 and even adding three new cases from their own experience. From the time their report was published until 2017, other 45 cases have been published ¹¹⁰⁻¹³⁰ and yet another was published in 1949 ⁴. In total, 92 cases of isolated malleus fractures have been published in the literature. Different types of otosurgical techniques have been used to correct this fracture: PORP ^{110,113}, TORP ¹¹⁵, bone chips ^{5,6}, cartilage ¹¹⁹, and bone cement ^{112,120} all with fairly good results; however, the gold standard has yet to be defined.

Two of these papers describe fractures of the malleus neck ^{129,130}. The case reported by Applebaum and Goldin in 2000 is described in the text as being a handle fracture, but according to the drawing it seems to be a fracture of the neck. The patient was treated with a custom-made bone chip placed between the fracture site and the incus, with postoperative normalization of the hearing. The patient had a conductive hearing loss, but the tympanometry results differed from those of other cases. While the usual finding when there is a fracture on the malleus handle is a high compliance, this patient had a low compliance. The patient described by Orabi in 2006 had been scratching her left ear, and her hearing deteriorated afterwards. Like for most fractures of the malleus handle, a hypermobile tympanometry and a mild conductive hearing loss in the mid and high frequencies was found for this patient. During exploration of the middle ear, the malleus was removed, and a fracture of the neck was identified. No further ossiculoplasty was performed.

The first sporadic reported cases from the 19th century were described with other co-existing injuries; most of the subjects were young men ². From these reports, it seems that although a trauma can lead to a malleus fracture, the digital trauma seems to be the one event causing only an isolated malleus fracture and nothing else. The fractures reported in our paper I have an even distribution between men (n=14) and women (n=14), and have digital trauma as the main cause of fracture (72%). In our paper from 2010 we found that eight out of nine patients had a history of digital trauma (89%). In the following years we have diagnosed about one new case per year (data not published), all of which had a self-inflicted trauma caused by digital manipulation of the ear canal. If this is recalculated into national estimates, the incidence would be of about 40 new cases per year in the entire Swedish population of ten million.

The exact mechanism of this digitally-caused malleus fracture is not yet clear. The vacuum force by the digital pull outwards could be enough to cause a fracture of the malleus handle. But if this is the only factor playing a role is not known. The action of the tensor tympany muscle with its opposite inward motion could also be a co-force. The typical fracture site of the malleus is often just distal to the insertion of the tensor tendon on the medial side of the malleus. The tensor muscle may contract in response to a rapid extension of the tendon. A non-functioning eustachian tube has also been suggested as a possible cause ¹²⁰. In our own cases no other coexisting diseases were found. Additionally, we found no significant differences in terms of time of the year of the event, or distribution between men and women.

It is not known why the number of men with traumatic malleus fractures has decreased, in favor of a more even gender distribution, together with an increasing number of digitally caused fractures. The shift from body work and a diminished exposure to accidents than that in the past might both influence these observations.

An interesting coincidence could be the introduction of running water in people's homes. At the end of 1850s, Stockholm started to build waterpipes in the city as a hygienic improvement, thanks to the new knowledge on the relation between cholerae and hygiene. Until then, people bathed and showered rarely. On the contrary, a common thought was that bathing was pointless and could even be harmful, in the sense that dirt could be a protective factor against diseases. It was not until 1938 that the real sanitary improvement took place in people's homes after a series of reports by the author Ludvig "Lubbe" Nordstrom ¹³¹ about the filth in Sweden. By the end of 1960, two thirds of the Swedish households had their own bathrooms, and by 1980 almost every house had one (96%). This concept of hygiene spread also in the rest of Europe at around this time. The malleus fractures, together with other lesions of the middle ear that were only rare incidents in the past, might still exist. In addition, a rather new type of isolated malleus fracture might partially have been caused by the more common activity of taking a bath or shower.

A patient with a malleus fracture suffers from a slight hearing loss and occasionally tinnitus. The causes and mechanisms of tinnitus have not been addressed in this study, despite almost half of the patients in our study suffered from it. We can briefly suggest that the force it takes to fracture a malleus handle might also be transferred to the cochlea, causing a minor inner ear damage and tinnitus. When comparing the BC on the affected side to the non-affected one, results usually show BC decreased by 3-5 dB. Patients will not always tell the whole story when visiting the physician: in fact, it is not uncommon that patients describe a water incident only after they have been specifically asked about it. At

otomicroscopy, the TM is often close to normal with an intact TM that, at first glance, has a normal appearance both at direct inspection and at pneumatic otoscopy. The handle of the malleus might have an unusual appearance and the TM usually has wrinkles distal to the umbo (Fig. 17). Palpation with a needle or a similar instrument may be helpful to check the mobility of the malleus. With pneumatic otoscopy this hypermobility is more evident if one is aware of the normal mobility, where the malleus moves very little compared to the TM. Hence, to clinically detect a malleus fracture the clinician must have the correct diagnosis in mind. The patient's history, a wrinkled TM near the umbo, an air-bone gap in the mid and high frequencies on the audiogram, and a hypermobility or double-peak type tympanometry will lead the clinician to the correct diagnosis.

Although the awareness of malleus fractures has increased, this condition is probably still under-diagnosed. Personnel working at primary health centers could pay more attention to anamnestic events such as patients that complain of sudden onset of hearing loss and tinnitus when they tried to remove water from the outer ear canal. Specialists working as otolaryngologists could pay more attention to patients with conductive hearing loss increasing towards higher frequencies and make a thorough pneumatic inspection of the TM. Personnel taking audiograms of patients could make a tympanometry when they observe an audiogram with a conductive hearing loss increasing towards the higher frequencies. This way we will probably find many more patients with isolated malleus fractures.

Paper II

Given the few cases of fractures of the malleus handle, randomized and controlled clinical studies investigating the optimal type of surgery are not easy to perform. As a result, human TBs were used in our LDV experiments. The fractured malleus handle on TBs were first compared with the normal ossicular chain and then divided in three groups, according to the type of surgery performed.

In this paper we compared three types of ossiculoplasties performed on a fracture of malleus handle. The three types of ossiculoplasties consisted of: stabilizing the fracture with bone cement, PORPs, and a custom-made malleus prosthesis (Fig 13). A similar prosthesis has also been described by Tos ⁸³. In paper II, all three types of ossiculoplasty showed a good but not full recovery of sound transmission. While the malleus stabilized with bone cement gave the best results, the malleus prosthesis and the PORPs gave similar, slightly worse results (Fig. 19).

The middle fossa approach we used differed from that of earlier studies in which the most common setting is through the mastoid by entering the middle ear cavity via a posterior tympanotomy. The advantages of our method are that less bone work is needed when the mastoid is left intact, and that the angle at which the

LDV is delivered is straight and not angled, as it is with the mastoid approach. Like in the mastoid approach, the middle ear with the TM is kept intact.

Various types of surgery and prostheses could be tested with this approach. In our setting we cut off the cochlea. This procedure might affect the results, since excluding the cochlear load could change the impedance of the movements of the stapes plate. Nevertheless, to our advantage all our results can be compared because we used the same setting. Furthermore, one advantage of this setting is that the cochlea does not add variability to our results. As a matter of fact, if the cochlea is not removed, the contained fluid can remain at a normal level or it can be partially or completely drained. How the amount of fluid contained in the cochlea affects the results of this kind of experiments is still debated in the literature. Lord et al.⁹⁰ found no change in stapes displacement above 1,000 Hz, and found a slight decrease in the lower frequencies when comparing intact versus drained cochlea after thawing frozen bones. Conversely, an increased stapes displacement between 600 and 2,200 Hz was shown in TBs with destroyed cochlea compared to those with an intact one³⁸. This result is also consistent with those of Hato et al. who found an increased stapes displacement after the cochlea had been drained³⁷. Both these latter studies were made on freshly collected TBs.

According to the LDV measurements, sound transmission differed depending on where at the malleus shaft the fracture was localized. Distal fractures showed very little effect on the sound transmission and the more proximal the fracture was, the worse the sound transmission became. Although our LDV data suggested different hearing results depending on the fracture site, our clinical findings (audiogram or tympanometry) did not differ much according to the fracture site¹¹⁰. However, distal fractures remain easier to deal with from a surgical point of view, since clinical results indicate that the hearing is almost completely restored after removal of the distal fractured part (paper I). The TM has two sites that are tightly attached to the malleus handle: the lateral process and the umbo. Between these two sites the attachment is looser. The LDV measurements we obtained were made both with and without the attachments to an intact malleus. Our results indicate that a tight attachment of the TM at these two sites seems to be very important for sound transmission (Fig. 20). This may explain why a PORP can give a good hearing, despite only a small part of the PORP is in contact with the TM.

Although this hypothesis was not tested in the present study, the importance of the two tight attachments of the TM (by the umbo and the lateral process) also suggests that it might be possible to leave the fractured malleus and only add a support using materials other than bone cement. For example, interposition of bone chips, cartilage or bone supporting the fracture by an underlying incus or stapes, could thus be a clinical alternative worth trying in the future^{125,129}.

Stabilization of a fractured malleus with bone cement seems to be the best option if the fractured parts are close to each other. This has also been shown clinically on patients ^{112,120}. However, in cases in which either it is difficult to get the fractured parts close to each other, or the distal part has atrophied, a PORP or TORP ¹¹⁵ is recommended. Malleus prostheses, however, need to be further tested in clinical settings.

Paper III

In many cases of malleus fracture, as well as in other diseases of the middle ear, the malleus handle cannot be restored, or it may be completely missing. Under these circumstances, the use of a PORP is a common option. We found that the PORPs could be divided into three groups, depending on their contact with the TM and the malleus handle. The groups were as follows: contact with the TM only, contact with the malleus handle only, and lateral contact both with the TM and the handle of the malleus (Fig. 14).

The prostheses that gave the best sound transmission were those in the group with both contact to the TM and the malleus handle (Fig. 21). Similar findings have also been described by Elbrond and Elpern ⁷⁵ who used human TBs and estimated the hearing by an acoustic method. In order to mimic the clinical condition of healing, a few PORPs were glued to the stapes and to the TM. The gluing of the PORPs resulted in an increased sound transmission when measured with LDV.

One of the advantages of the present study was that we used the setup described in paper II: this allowed us to easily make repeated measurements and to test many different PORPs in the same TBs and within a short time span.

As stated in the introduction, it would be impossible to perform clinical studies to compare all variants of PORPs/TORPs regarding their sound transmission capabilities. In paper III we have shown that our TB and LDV method is a suitable tool for evaluating sound transmission capability of different PORPs.

As we also reported in paper II, the best fit for the prosthesis was a loose fit, which has also been confirmed by other groups, as mentioned in the chapter “Surgery of the ossicular chain”. The “best fit” means that if we did not obtain a good sound transmission at the first try, we did small adjustments and then measured again. A weakness of both study II and III, is the rather small number of TBs, which made the statistical analysis weaker. However, our results are interesting in that they encourage future clinical studies, as they indicate that an optimal PORP should have contact with both the TM and the malleus handle.

Paper IV

It is not known if the lack of healing of the malleus fractures is caused by the inability of the malleus to remodel itself, or if the small movements in a fractured malleus prevent its bone healing. Therefore, an animal model was developed to investigate the bone healing capabilities of malleus. The sheep (n=9) served as their own controls, as fractures from different sites of the head were compared with the malleus fractures. Only the right ear was operated in order not to impair the hearing on both ears. The types of malleus fractures were divided in: unstabilized, stabilized with bony cement, and “stabilized” by making only a drill hole in the malleus neck. The three control sites were chosen to be the mandible, due to the common embryologic origin, the nose, due to the known healing properties, and finally the bony outer ear canal, due to its closeness to the TB (Table 3).

All sheep showed good well-being during the four postoperative weeks, after which they were sacrificed. Analysis of the fracture sites by micro-CT showed no bone formation at the malleus fractures whereas new bone formation at the control sites was seen. Histology testing will be performed in the future in order to further analyze the types of healing processes at these sites. The findings reported above implicate that stabilization of a malleus fracture with, for example, bone cement needs to be permanently stable enough since there will be no callus formation at the fracture site. This finding is in accordance with previous observations on lack of bone formation in the otic capsule and ossicles.

Conclusion

Paper I

Digital trauma is the major cause of isolated malleus fractures. The hearing loss is occasionally accompanied by tinnitus. Pneumatic otoscopy and tympanometry show a hypermobile TM and the audiometry usually shows a conductive hearing loss increasing towards the higher frequencies.

Paper II

A new TB model was designed to measure the outcome of different ossiculoplasties by LDV. Fixation of the malleus fracture with bone cement showed the best sound transmission, but a custom-made prosthesis or a PORP are also valuable alternative treatments.

Paper III

A PORP in contact with both the malleus handle and the TM had the best sound transmission in our TB model and could be recommended for clinical use.

Paper IV

In an *in vivo* sheep model, we successfully tested the retroauricular approach and the sheep showed good well-being. We studied the bone healing properties in the middle ear and compared them to those of the mandible and nasal bone. Micro-CT examinations after four weeks showed that, in contrast to the mandible and nasal fractures, the malleus fracture had no signs of bone healing.

Future perspectives

To get a better understanding of the tensor tympany muscle and its effect on malleus fractures. This might be feasible in an animal model or maybe even in a human *in vivo* model.

An LDV study on malleus fracture with interposition of a columella from beneath. The finding reported in paper II about the importance of the two tightly connected sites (the umbo and the lateral process) may be explored more thoroughly.

An LDV study using a custom-made net with a shape memory around the malleus fracture. This idea is similar to that of the Nitinol stapes prosthesis.

Clinical studies of malleus prostheses as those presented in paper II.

Histology results from the samples presented in paper IV will hopefully give important insights on bone remodeling in the ossicles.

An animal model using bone stimulating agents. This has partially been successful in a study on osseointegration of titanium prostheses on the stapes in a sheep model.

An animal model, using bone chips at the site of the fracture. This has been published in a few case reports that succeeded in restoring hearing postoperatively. Is bone remodeling operated by osteoblasts from the bone chip at the site of fracture or is the bone chip just a passive stabilizer?

Acknowledgement

I wish to express my sincere gratitude to the following persons during my work with this thesis.

Krister Tano. My main supervisor during this work. I think you tricked me into this project and without you and your endless support this would not have happened, thank you!

Magnus von Unge. My co-supervisor during this work. Thank you for all support and wisdom. Always full of energy, new ideas and joy.

Anton Rönnblom. My friend, colleague, and research fellow through this work. Thank you for all the late and early hours discussing difficulties and joy that work, research and life can bring.

The Antwerp team: Joris Dirckx, Pieter Muyshondt, Kilian Gladiné and John Peacock, my mentors in the world of physics and laser Doppler vibrometry.

The Perth team: Rodney Dilley, Gabrielle Musk, Sharon Redmond, Nathan Pavlos and Hsien Tan. The weeks we spent together in Perth will be a vibrant memory for the rest of my life.

The Umeå team: Diana Berggren, Mimmi Werner, Torbjörn Holmlund, Anders Behndig and Claude Laurent. Thank you for your feedback during this work. It made the thesis better, and I am still standing!

Malou Hultcrantz, for the valuable feedback at the mid seminar.

The staff at the ENT department in Piteå with a special thanks to Helena Henriksson, Nina Holmgren and Maria Toivianen for all the help with the temporal bones. Sten-Hermann Schmidt for your guidance at my start in the field of otorhinolaryngology.

The staff at the ENT department at Sunderby hospital with a special thanks to Eva Barrelöv and my friend and colleague Mikael Wannerberg for all your support.

Lennart Edfeldt, Karin Strömbäck and Marie Bunne for your guidance in otosurgery.

Åke Dahlqvist, I am proud to have been one of your research fellows.

Ulf Mercke my friend and mentor in the world of otosurgery.

To the wonderful people at Hermelinen in Luleå, with a special thanks to my friend Tomas Isaksson for the opportunity to work with you all.

Anna Lundberg at Umeå University, for your help getting financial support.

Sister Julia Eriksson for all the tech support.

My, for your love.

Nils, Erik, Gustav, my wonderful sons. Thank you for the tech support and proof reading. You are my number ones!

Financial disclosure

I also wish to express my gratitude to the following contributors for their financial support during this project:

The Acta Oto-Laryngologica Foundation, Sweden

Svenska Läkarsällskapet (Frenknerns Foundation), Sweden (SLS-587481).

The Research Council of the County of Norrbotten, Sweden (Akademisk miljö, Krister Tano, NLL-316201, NLL-47081).

I wish to thank Viviana Moroso (MSc, PhD) of MV Medical Writing (Luleå, Sweden) for providing medical writing support for this thesis, which was funded by the Research Council of the County of Norrbotten, Sweden, in accordance with Good Publication Practice (GPP3) guidelines (<http://www.ismpps.org/gpp3>).

References

1. Menière P. Memoire sur les sequesters osseux observes dans les diverses parties de l'appareil auditif. Vingt-septieme Annee, 3e Serie, Tome Douzieme. Gaz Med Paris, 1857:780-783.
2. Drury DW. Fractures of the malleus. The Laryngoscope 1925; 35:345-353.
3. Weir RF. Ununited fracture of the long process of the malleus. Am Otol Soc 1870:91-92.
4. Keller AP, Jr. Fracture of the malleus. Eye Ear Nose Throat Mon 1949; 28:531.
5. Harris JP, Butler D. Recognition of malleus handle fracture in the differential diagnosis of otologic trauma. Laryngoscope 1985; 95:665-670.
6. Pedersen CB. Traumatic middle ear lesions. Fracture of the malleus handle, aetiology, diagnosis and treatment. J Laryngol Otol 1989; 103:901-903.
7. Hüttenbrink KB. The mechanics of the middle-ear at static air pressures: the role of the ossicular joints, the function of the middle-ear muscles and the behaviour of stapelial prostheses. Acta Otolaryngol Suppl 1988; 451:1-35.
8. Von Békésy G, Wever EG. Experiments in hearing. McGraw-Hill New York, 1960.
9. Chien W, Northrop C, Levine S, et al. Anatomy of the distal incus in humans. Journal of the Association for Research in Otolaryngology : JARO 2009; 10:485-496.
10. Merchant SN, Nadol JB. Schuknecht's Pathology of the Ear. PMPH-USA, 2010.
11. Proctor B. The development of the middle ear spaces and their surgical significance. J Laryngol Otol 1964; 78:631-648.
12. Marotti G, Farneti D, Remaggi F, Tartari F. Morphometric investigation on osteocytes in human auditory ossicles. Annals of anatomy. 1998; 180:449-453.
13. Anson BJ, Winch TR. Vascular channels in the auditory ossicles in man. Ann Otol Rhinol Laryngol 1974; 83:142-158.
14. De Greef D, Buytaert JA, Aerts JR, Van Hoorebeke L, Dierick M, Dirckx J. Details of human middle ear morphology based on micro-CT imaging of phosphotungstic acid stained samples. J Morphol 2015; 276:1025-1046.
15. Anthwal N, Joshi L, Tucker AS. Evolution of the mammalian middle ear and jaw: adaptations and novel structures. J Anat 2013; 222:147-160.
16. Thompson H, Ohazama A, Sharpe PT, Tucker AS. The origin of the stapes and relationship to the otic capsule and oval window. Dev Dyn 2012; 241:1396-1404.
17. Manley GA. An evolutionary perspective on middle ears. Hear Res 2010; 263:3-8.

18. Puria S, Steele C. Tympanic-membrane and malleus-incus-complex co-adaptations for high-frequency hearing in mammals. *Hear Res* 2010; 263:183-190.
19. Fritzsche B, Barald KF, Lomax MI. Early embryology of the vertebrate ear Development of the auditory system: Springer, 1998:80-145.
20. Sørensen MS. Temporal bone dynamics, the hard way. Formation, growth, modeling, repair and quantum type bone remodeling in the otic capsule. *Acta Otolaryngol Suppl* 1994; 512:1-22.
21. Palumbo C, Cavani F, Sena P, Benincasa M, Ferretti M. Osteocyte apoptosis and absence of bone remodeling in human auditory ossicles and scleral ossicles of lower vertebrates: a mere coincidence or linked processes? *Calcif Tissue Int* 2012; 90:211-218.
22. Kakizaki I, Zechner G, Altmann F. The osteocytes of the human labyrinthine capsule. *Arch Otolaryngol* 1971; 94:139-150.
23. Bloch SL, McKenna MJ, Adams J, Friis M. Labyrinthitis Ossificans: On the Mechanism of Perilabyrinthine Bone Remodeling. *Ann Otol Rhinol Laryngol* 2015; 124:649-654.
24. Frisch T, Sørensen MS, Overgaard S, Bretlau P. Estimation of volume referent bone turnover in the otic capsule after sequential point labeling. *Ann Otol Rhinol Laryngol* 2000; 109:33-39.
25. Milroy CM, Michaels L. Pathology of the otic capsule. *J Laryngol Otol* 1990; 104:83-90.
26. Salomonsen RL, Hermansson A, Caye-Thomasen P. Ossicular bone modeling in acute otitis media. *Otol Neurotol* 2010; 31:1109-1114.
27. Zehnder AF, Kristiansen AG, Adams JC, Kujawa SG, Merchant SN, McKenna MJ. Osteoprotegerin knockout mice demonstrate abnormal remodeling of the otic capsule and progressive hearing loss. *Laryngoscope* 2006; 116:201-206.
28. Bloch SL. On the biology of the bony otic capsule and the pathogenesis of otosclerosis. *Dan Med J* 2012; 59:B4524.
29. Kanzaki S, Ito M, Takada Y, Ogawa K, Matsuo K. Resorption of auditory ossicles and hearing loss in mice lacking osteoprotegerin. *Bone* 2006; 39:414-419.
30. Kringelbotn M. Network model for the human middle ear. *Scand Audiol* 1988; 17:75-85.
31. Tonndorf J, Khanna SM. The role of the tympanic membrane in middle ear transmission. *Ann Otol Rhinol Laryngol* 1970; 79:743-753.
32. Gerig R, Ihrle S, Roosli C, et al. Contribution of the incudo-malleolar joint to middle-ear sound transmission. *Hear Res* 2015; 327:218-226.
33. Gottlieb PK, Vaisbuch Y, Puria S. Human ossicular-joint flexibility transforms the peak amplitude and width of impulsive acoustic stimuli. *J Acoust Soc Am* 2018; 143:3418.
34. Nakajima HH, Ravicz ME, Merchant SN, Peake WT, Rosowski JJ. Experimental ossicular fixations and the middle ear's response to sound: evidence for a flexible ossicular chain. *Hear Res* 2005; 204:60-77.
35. Elpern B, Greisen O, Andersen H. JAO-L. Experimental studies on sound transmission in the human ear: VI. Clinical and experimental observations on non-otosclerotic ossicle fixation 1965; 60:223-230.

36. Alian W, Majdalawieh O, Kieft M, Ejnell H, Bance M. The effect of increased stiffness of the incudostapedial joint on the transmission of air-conducted sound by the human middle ear. *Otol Neurotol* 2013; 34:1503-1509.
37. Hato N, Stenfelt S, Goode RL. Three-dimensional stapes footplate motion in human temporal bones. *Audiol Neurotol* 2003; 8:140-152.
38. Gyo K, Aritomo H, Goode RL. Measurement of the ossicular vibration ratio in human temporal bones by use of a video measuring system. *Acta Otolaryngol* 1987; 103:87-95.
39. Vlaming M, Feenstra L. Studies on the mechanics of the normal human middle ear. *Clin Otolaryngol* 1986; 11:353-363.
40. Heiland KE, Goode RL, Asai M, Huber AM. A human temporal bone study of stapes footplate movement. *Am J Otol* 1999; 20:81-86.
41. Voss SE, Rosowski JJ, Merchant SN, Peake WT. Acoustic responses of the human middle ear. *Hear Res* 2000; 150:43-69.
42. Mukerji S, Windsor AM, Lee DJ. Auditory brainstem circuits that mediate the middle ear muscle reflex. *Trends Amplif* 2010; 14:170-191.
43. Klockhoff I, Anderson H. Reflex activity in the tensor tympani muscle recorded in man; preliminary report. *Acta Otolaryngol* 1960; 51:184-188.
44. Klockhoff I. Middle ear muscle reflexes in man: a clinical experimental study with special reference to diagnostic problems in hearing impairment. *Acta Otolaryngol*, 1961:1-92.
45. Bance M, Makki FM, Garland P, Alian WA, van Wijhe RG, Savage J. Effects of tensor tympani muscle contraction on the middle ear and markers of a contracted muscle. *Laryngoscope* 2013; 123:1021-1027.
46. Marquet J. The incudo-malleal joint. *J Laryngol Otol* 1981; 95:543-565.
47. Sesterhenn G, Breuninger H. On the influence of the middle ear muscles upon changes in sound transmission. *Arch Otorhinolaryngol* 1978; 221:47-60.
48. Stenfelt S, Goode RL. Bone-conducted sound: physiological and clinical aspects. *Otol Neurotol* 2005; 26:1245-1261.
49. Peake WT, Rosowski JJ, Lynch TJ III. Middle-ear transmission: acoustic versus ossicular coupling in cat and human. *Hear Res* 1992; 57:245-268.
50. Merchant SN, Ravicz ME, Voss SE, Peake WT, Rosowski JJ. *J Laryngol Otol*. Middle ear mechanics in normal, diseased and reconstructed ears 1998; 112:715-731.
51. Voss SE, Rosowski JJ, Merchant SN, Peake WT. Non-ossicular signal transmission in human middle ears: Experimental assessment of the "acoustic route" with perforated tympanic membranes. *J Acoust Soc Am* 2007; 122:2135-2153.
52. Terkildsen K, Thomsen KA. The Influence of Pressure Variations on the Impedance of the Human Ear Drum: A method for Objective Determination of the Middle-Ear Pressure. *J Laryngol Otol*, 73(7) 1959:409-418.
53. Margolis RH, Van Camp KJ, Wilson RH, Creten WL. Multifrequency tympanometry in normal ears. *Audiology* 1985; 24:44-53.

54. Colletti V. Tympanometry from 200 to 2000 Hz probe tone. *Audiology* 1976; 15:106-119.
55. Colletti V. Multifrequency tympanometry. *Audiology* 1977; 16:278-287.
56. Wallis S, Atkinson H, Coatesworth AP. Chronic otitis media. *Postgrad Med* 2015; 127:391-395.
57. Yung M, Tono T, Olszewska E, et al. EAONO/JOS Joint Consensus Statements on the Definitions, Classification and Staging of Middle Ear Cholesteatoma. *J Int Adv Otol* 2017; 13:1-8.
58. Thomas JP, Minovi A, Dazert S. Current aspects of etiology, diagnosis and therapy of otosclerosis. *Otolaryngol Pol* 2011; 65:162-170.
59. Rudic M, Keogh I, Wagner R, et al. The pathophysiology of otosclerosis: Review of current research. *Hear Res* 2015; 330:51-56.
60. Lippy WH, Berenholz LP, Schuring AG, Burkey JM. Does pregnancy affect otosclerosis? *Laryngoscope* 2005; 115:1833-1836.
61. Batson L, Rizzolo D. Otosclerosis: An update on diagnosis and treatment. *Jaapa* 2017; 30:17-22.
62. Carhart R. Clinical application of bone conduction audiometry. *Arch Otolaryngol* 1950; 51:798-808.
63. Kashio A, Ito K, Kakigi A, et al. Carhart notch 2-kHz bone conduction threshold dip: a nondefinitive predictor of stapes fixation in conductive hearing loss with normal tympanic membrane. *Arch Otolaryngol Head Neck Surg* 2011; 137:236-240.
64. Ahmad I, Pahor AL. Carhart's notch: a finding in otitis media with effusion. *Int J Pediatr Otorhinolaryngol* 2002; 64:165-170.
65. Homma K, Du Y, Shimizu Y, Puria S. Ossicular resonance modes of the human middle ear for bone and air conduction. *J Acoust Soc Am* 2009; 125:968-979.
66. Stenfelt S. Inner ear contribution to bone conduction hearing in the human. *Hear Res* 2015; 329:41-51.
67. Wullstein H. Theory and practice of tympanoplasty. *Laryngoscope* 1956; 66:1076-1093.
68. Zollner F. The principles of plastic surgery of the sound-conducting apparatus. *J Laryngol Otol* 1955; 69:637-652.
69. Rosowski JJ, Merchant SN. Mechanical and acoustic analysis of middle ear reconstruction. *Am J Otol* 1995; 16:486-497.
70. Nishihara S, Goode RL. Experimental study of the acoustic properties of incus replacement prostheses in a human temporal bone model. *Am J Otol* 1994; 15:485-494.
71. Vlaming MS, Feenstra L. Studies on the mechanics of the reconstructed human middle ear. *Clin Otolaryngol Allied Sci* 1986; 11:411-422.
72. Ulku CH, Cheng JT, Guignard J, Rosowski JJ. Comparisons of the mechanics of partial and total ossicular replacement prostheses with cartilage in a cadaveric temporal bone preparation. *Acta Otolaryngol* 2014; 134:776-784.
73. Bance M, Morris DP, Vanwijhe RG, Kieffe M, Funnell WR. Comparison of the mechanical performance of ossiculoplasty using a prosthetic malleus-to-stapes head with a tympanic membrane-to-stapes head assembly in a human cadaveric middle ear model. *Otol Neurotol* 2004; 25:903-909.

74. Neudert M, Bornitz M, Lasurashvili N, Schmidt U, Beleites T, Zahnert T. Impact of Prosthesis Length on Tympanic Membrane's and Annular Ligament's Stiffness and the Resulting Middle Ear Sound Transmission. *Otol Neurotol* 2016; 37:e369-376.
75. Elbrond O, Elpern BS. Reconstruction of ossicular chain in incus defects. An experimental study. *Arch Otolaryngol* 1965; 82:603-608.
76. Morris DP, Bance M, van Wijhe RG, Kieft M, Smith R. Optimum tension for partial ossicular replacement prosthesis reconstruction in the human middle ear. *Laryngoscope* 2004; 114:305-308.
77. Brackmann DE, Sheehy JL, Luxford WM. TORPs and PORPs in tympanoplasty: a review of 1042 operations. *Otolaryngol Head Neck Surg* 1984; 92:32-37.
78. Merchant SN, Rosowski JJ, McKenna MJ. Tympanoplasty. *Operative Techniques in Otolaryngology-Head and Neck Surgery* 2003; 14:224-236.
79. Colletti V, Fiorino FG, Sittoni V. Minisculptured ossicle grafts versus implants: long-term results. *Am J Otol.* 1987; 8:553-559.
80. Murugasu E, Puria S, Roberson JB, Jr. Malleus-to-footplate versus malleus-to-stapes-head ossicular reconstruction prostheses: temporal bone pressure gain measurements and clinical audiological data. *Otol Neurotol* 2005; 26:572-582.
81. Vincent R, Sperling NM, Oates J, Osborne J. Ossiculoplasty with intact stapes and absent malleus: the silastic banding technique. *Otol Neurotol* 2005; 26:846-852.
82. Neudert M, Zahnert T, Lasurashvili N, Bornitz M, Lavcheva Z, Offergeld C. Partial ossicular reconstruction: comparison of three different prostheses in clinical and experimental studies. *Otol Neurotol* 2009; 30:332-338.
83. Tos M. *Manual of middle ear surgery.* Georg Thieme Stuttgart, 1993.
84. Goode RL, Ball G, Nishihara S. Measurement of umbo vibration in human subjects--method and possible clinical applications. *Am J Otol* 1993; 14:247-251.
85. Rosowski JJ, Davis PJ, Merchant SN, Donahue KM, Coltrera MD. Cadaver middle ears as models for living ears: comparisons of middle ear input immittance. *Ann Otol Rhinol Laryngol* 1990; 99:403-412.
86. Voss SE, Rosowski JJ, Merchant SN, Peake WT. Acoustic responses of the human middle ear 2000; 150:43-69.
87. Merchant SN, Ravicz ME, Rosowski JJ. Acoustic input impedance of the stapes and cochlea in human temporal bones. *Hear Res* 1996; 97:30-45.
88. Ravicz ME, Merchant SN, Rosowski JJ. Effect of freezing and thawing on stapes-cochlear input impedance in human temporal bones. *Hear Res* 2000; 150:215-224.
89. Schon F, Muller J. Measurements of ossicular vibrations in the middle ear. *Audiol Neurotol* 1999; 4:142-149.
90. Lord RM, Abel EW, Wang Z, Mills RP. Effects of draining cochlear fluids on stapes displacement in human middle-ear models. *J Acoust Soc Am* 2001; 110:3132-3139.
91. Ravicz ME, Rosowski JJ, Merchant SN. Mechanisms of hearing loss resulting from middle-ear fluid. *Hear Res* 2004; 195:103-130.

92. Goode RL, Killion M, Nakamura K, Nishihara S. New knowledge about the function of the human middle ear: development of an improved analog model. *Am J Otol* 1994; 15:145-154.
93. Kurokawa H, Goode RL. Sound pressure gain produced by the human middle ear. *Otolaryngol Head Neck Surg* 1995; 113:349-355.
94. Hellstrom S, Salen B, Stenfors LE. Anatomy of the rat middle ear. A study under the dissection microscope. *Acta Anat (Basel)* 1982; 112:346-352.
95. Ravicz ME, Rosowski JJ. Chinchilla middle ear transmission matrix model and middle-ear flexibility. *J Acoust Soc Am* 2017; 141:3274.
96. Von Unge M, Buytaert J, Dirckx J. Anatomical boundary of the tympanic membrane pars flaccida of the *Meriones unguiculatus* (Mongolian gerbil). *Anat Rec (Hoboken)* 2011; 294:987-995.
97. Wang X, Guan X, Pineda M, Gan RZ. Motion of tympanic membrane in guinea pig otitis media model measured by scanning laser Doppler vibrometry. *Hear Res* 2016; 339:184-194.
98. Peacock J, Pintelon R, Dirckx J. Nonlinear Vibration Response Measured at Umbo and Stapes in the Rabbit Middle ear. *Journal of the Association for Research in Otolaryngology : JARO* 2015; 16:569-580.
99. Ladak HM, Funnell WR. Finite-element modeling of the normal and surgically repaired cat middle ear. *J Acoust Soc Am* 1996; 100:933-944.
100. Schnabl J, Glueckert R, Feuchtnner G, et al. Sheep as a large animal model for middle and inner ear implantable hearing devices: a feasibility study in cadavers. *Otol Neurotol* 2012; 33:481-489.
101. Seibel VA, Lavinsky L, De Oliveira JA. Morphometric study of the external and middle ear anatomy in sheep: a possible model for ear experiments. *Clin Anat* 2006; 19:503-509.
102. Seibel VA, Lavinsky L, Irion K. CT-Scan sheep and human inner ear morphometric comparison. *Braz J Otorhinolaryngol* 2006; 72:370-376.
103. Soares HB, Lavinsky L. Histology of sheep temporal bone. *Braz J Otorhinolaryngol* 2011; 77:285-292.
104. Lavinsky L, Goycoolea M, Gananca MM, Zwetsch Y. Surgical treatment of vertigo by utriculostomy: an experimental study in sheep. *Acta Otolaryngol* 1999; 119:522-527.
105. Anschuetz L, Bonali M, Ghirelli M, et al. An Ovine Model for Exclusive Endoscopic Ear Surgery. *JAMA otolaryngology-- head & neck surgery* 2017; 143:247-252.
106. Cordero A, Benitez S, Reyes P, et al. Ovine ear model for fully endoscopic stapedectomy training. *Eur Arch Otorhinolaryngol* 2015; 272:2167-2174.
107. Peus D, Dobrev I, Prochazka L, et al. Sheep as a large animal ear model: Middle-ear ossicular velocities and intracochlear sound pressure. *Hear Res* 2017; 351:88-97.
108. Neudert M, Beleites T, Ney M, et al. Osseointegration of titanium prostheses on the stapes footplate. *Journal of the Association for Research in Otolaryngology : JARO* 2010; 11:161-171.
109. Musk GC, Kershaw H, Tano K, Niklasson A, von Unge M, Dilley RJ. Reactions to Gudair(R) vaccination identified in sheep used for biomedical research. *Aust Vet J* 2019.

110. Niklasson A, Tano K. Self-inflicted negative pressure of the external ear canal: a common cause of isolated malleus fractures. *Acta Otolaryngol* 2010; 130:410-416.
111. Iurato S, Quaranta A. Malleus-handle fracture: historical review and three new cases. *Am J Otol* 1999; 20:19-25.
112. Hato N, Okada M, Hakuba N, Hyodo M, Gyo K. Repair of a malleus-handle fracture using calcium phosphate bone cement. *Laryngoscope* 2007; 117:361-363.
113. Chien W, McKenna MJ, Rosowski JJ, Merchant SN. Isolated fracture of the manubrium of the malleus. *J Laryngol Otol* 2008; 122:898-904.
114. Punke C, Pau HW. Isolated fracture of the handle of malleus. A rare differential diagnosis in cases of conductive hearing loss. *HNO* 2006; 54:121-124.
115. Abo-Khatwa M, Addams-Williams J, Vincent R, Osborne J. Malleus-handle fracture: literature review and a new surgical approach. *Internet J Otorhinolaryngol* 2005; 4:3353.
116. Ozturk O, Uneri C. Isolated fracture of the malleus handle. *Otolaryngol Head Neck Surg* 2009; 141:653-654.
117. Blanchard M, Abergel A, Verillaud B, Williams MT, Ayache D. Isolated malleus-handle fracture. *Auris Nasus Larynx* 2011; 38:439-443.
118. Casale M, De Franco A, Rinaldi V, Zini C, Salvinelli F. Isolated fracture of the malleus handle: a video clip. *Laryngoscope* 2010; 120:813-814.
119. Chang YN, Hung CC, Lee JC, Wang CH. Isolated malleus-handle fracture surgical repair using tragal cartilage. *Am J Otolaryngol* 2011; 32:77-79.
120. Delrue S, De Foer B, van Dinther J, et al. Handling an Isolated Malleus Handle Fracture: Current Diagnostic Work-up and Treatment Options. *Ann Otol Rhinol Laryngol* 2015; 124:244-249.
121. Tan M, Ullman N, Pearl MS, Carey JP. Fracture of the Manubrium of the Malleus. *Otol Neurotol* 2016; 37:e254-255.
122. Yetiser S. An isolated traumatic fracture of the malleus handle. *Clinical case reports* 2017; 5:1197.
123. Sy A, Regonne EJ, Ndiaye M, Thill MP. Isolated malleus handle fracture: Two case reports. *Egyptian Journal of Ear, Nose, Throat and Allied Sciences* 2017.
124. Stapper M, Stange T. A rare case of conductive hearing loss : Isolated fracture of the manubrium mallei as a consequence of digital manipulation in the external auditory meatus. *HNO* 2017; 65:251-255.
125. Baijens LW, Manni JJ. *JAM*. Isolated Malleus Handle Fracture: Case Report 2005; 3:121-123.
126. Toquet J, Malard O, Bordure P, Legent F. LES C. D´ORL, de chirurgie cervico-faciale et d'audiophonologie. Les fractures isolées du manche du marteau 2000; 35:174-182.
127. Ilan O, Bermanb P, Sosnab J, Grossa M. Middle ear virtual endoscopy in malleus fracture and dislocation. *Open Otorhinolaryngology Journal* 2008; 2:23-25.
128. Choi J, Tu N, Go J, Kari E. *ENT-journal*. Recognizing malleus fracture in a woman with a head injury after a fall 2017; 96:E31.

129. Applebaum EL, Goldin AD. Surgical management of isolated malleus handle fractures. *Laryngoscope* 2000; 110:171-173.
130. Orabi AA. Isolated malleus neck fracture. *Acta Otolaryngol* 2006; 126:321-323.
131. Nordström L. *Lort-Sverige*. 1938.