

UMEÅ UNIVERSITY ODONTOLOGICAL DISSERTATIONS

From the Department of Oral and Maxillofacial Surgery.

Umeå University, SE-90187, Umeå, Sweden

**Bone healing after implantation of bone substitute materials.**

**Experimental studies in estrogen deficiency.**

**Sven Öberg**



Umeå 2003

Department of Oral and Maxillofacial Surgery, Umeå University

Department of Oral Surgery and Oral Medicine, Malmö University

Department of Biomaterials Sciences, Institute of Surgical Sciences, Göteborg University

Copyright © Sven Öberg 2003

**Bone healing after implantation of bone substitute materials.**

**Experimental studies in estrogen deficiency.**

**ISSN 0345-7532 no 81**

**ISBN 91-7305-504-2**

Department of Oral and Maxillofacial Surgery

Umeå University, SE-90187 Umeå, Sweden

Printed by: Print & Media, Umeå University 2003:309082

# Table of contents

<b>ABSTRACT</b>	<b>5</b>
<b>ORIGINAL PAPERS</b>	<b>6</b>
<b>INTRODUCTION</b>	<b>7</b>
Bone healing	7
Bone grafting	8
Bone substitutes	9
BMP and demineralised bone matrix	11
Reconstruction with dental implants	12
Osteoporosis	13
Handling of material	14
<b>AIMS</b>	<b>15</b>
<b>MATERIAL AND METHODS</b>	<b>16</b>
AAA-bone preparations	16
Animals	17
Specimen preparations and analysis	17
Blood	17
DEXA	18
Fibrin glue	18
Paper I	19
Paper II	20
Paper III	22
Paper IV	22
Paper V	23
Statistics	24
<b>RESULTS</b>	<b>25</b>
Paper I	25
Paper II	26

<b>Paper III</b>	<b>28</b>
<b>Paper IV</b>	<b>30</b>
<b>Paper V</b>	<b>31</b>

<b>DISCUSSION</b>	<b>34</b>
<b>Research animals</b>	<b>34</b>
<b>Observation times</b>	<b>34</b>
<b>Implant material</b>	<b>35</b>
<b>Fibrin glue</b>	<b>37</b>
<b>Preparation of sections for histological analysis</b>	<b>38</b>
<b>Morphometrics</b>	<b>38</b>
<b>Implant stability</b>	<b>38</b>
<b>Experimental osteopenia</b>	<b>39</b>
<b>Hydroxyapatite and AAA-bone</b>	<b>40</b>
<b>Bone healing and estrogen deficiency</b>	<b>41</b>

<b>CONCLUSIONS</b>	<b>42</b>
--------------------	-----------

<b>ACKNOWLEDGEMENTS</b>	<b>43</b>
-------------------------	-----------

<b>REFERENCES</b>	<b>44</b>
-------------------	-----------

**PAPER I**

**PAPER II**

**PAPER III**

**PAPER IV**

**PAPER V**



# Abstract

Bone formation and bone healing were studied in the mandible, tibia and skull bones in adult, healthy and estrogen deficient rabbits implanted with different bone substitutes. In the first study an evaluation of the differences in bone regeneration in and around solid (Alveograf®) and porous hydroxyapatite (Interpore 200®) was undertaken. The implant material was placed into experimentally made bone defects and in half of the defects hydroxyapatite was mixed with a fibrin sealant (Tisseel®). The material alone or mixed with Tisseel was also placed subperiostally in the mandible. The observation time was six month. No difference in bone regeneration was found between solid or porous hydroxyapatite granulas and the addition of Tisseel® did not seem to disturb the bone healing process. The implant material placed subperiostally did not induce bone formation nor did it provoke any bone resorption. The addition of Tisseel made the implant material much easier to handle and retain in the tissue during surgery. Bone healing around hydroxyapatite implants was also evaluated in the second study. Experimental cavities in the mandible and tibia were filled with hydroxyapatite in granules or blocks (Interpore 200®) but now with or without autolyzed, antigen-extracted, allogeneic bone (AAA). Also in this study Tisseel® was used to facilitate the handling of the material. All cavities implanted with AAA-bone, regardless of the combination with hydroxyapatite or Tisseel, demonstrated excessive bone formation resembling exostosis formation. Thus, hydroxyapatite, both as granules and blocks, can be successfully combined with AAA bone utilizing the bone inductive capacity of AAA bone. The same model was used to study the healing in ovariectomized animals in the third study. Bone cavities were implanted with or without AAA bone and left to heal. The results indicate that the osteoinductive capacity of AAA bone is in operation also in animals deprived of a normal estrogen production. The effect of using AAA bone prior to implant insertion was studied in paper four. The bone-implant contact was significant higher when AAA bone had been used. The implant stability did not seem to be affected. In paper five defects were made in skull and tibial bone in estrogen deficient animals. The deficiency of estrogen was confirmed through blood analysis, the decrease in the weight of uterus and bone mineral density. The whole body scanning with DEXA showed that the ovariectomized animals developed osteopenia. Various degree of bone formation was seen in the defects due to the influence of the bone inductive substance AAA bone. The studies indicate that a conductive material like hydroxyapatite in granules or blocks could be useful in oral reconstructive surgery. The combination with AAA bone enhanced the bone formation in calvarial and tibial bone in healthy and estrogen deficient animals. Tisseel® could be used to facilitate handling and retention of the material in the intended position during the healing process without negative effects.

**Key words:** Bone grafts, hydroxyapatite, estrogen deficiency, demineralised bone, bone formation, AAA bone, bone defect, titanium implants, resonance frequency analysis

# Original papers

This dissertation is based on the following papers, which will be referred to in the text by their Roman numerals (papers reprinted by kind permission of journal editors):

- I           **S. Öberg, K-E Kahnberg.** Combined use of hydroxyapatite and Tisseel® in experimental bone defects in the rabbit.  
Swed Dent J 1993;17:147-153.
  
- II           **S. Öberg, J.B. Rosenquist.** Bone healing after implantation of hydroxyapatite granules and blocks (Interpore 200®) combined with autolyzed antigen-extracted allogeneic bone and fibrin glue.  
Int. J. Oral Maxillofacial. Surg. 1994; 23:110-114.
  
- III           **S. Öberg, C. Johansson, J. B. Rosenquist.** Bone formation after implantation of autolyzed antigen-extracted allogeneic bone in ovariectomized rabbits.  
Int. J. Oral Maxillofacial. Surg. 2003; 32; 00-00  
doi:10.1054/ijoms.2002.0428
  
- IV           **S. Öberg, L. Sennerby.** Integration of titanium implants in bone defects reconstructed with autolyzed antigen extracted allogeneic (AAA) bone powder prior to implant placement.  
A histological and resonance frequency analysis study in the rabbit.  
Submitted
  
- V           **S. Öberg, J. B. Rosenquist, M. Gordh.** Healing of bone defects in osteopenic rabbits. Effect of autolyzed antigen extracted allogeneic bone substitute on calvarial and tibial bone.  
In manuscript.

# Introduction

Bone tissue constitutes the major part of the skeleton, which is the main supportive organ of the body. The different bones are designed to withstand the particular load applied to them and consequently they vary in shape and composition. In addition to other functions the bone tissue through its cellular components serves as part of the system regulating the calcium metabolism.

The human bone consists mainly of two tissue forms, cortical and trabecular. The compact cortical bone has a high mineral content mainly of hydroxyapatite, and little soft tissue. It can therefore withstand the forces applied on the skeletal during function. The soft trabecular bone on the other hand has a low content of minerals and comparatively more soft tissue per volume.

There are three types of bone cells with progenitor cells. The osteoblasts are responsible for the formation of bone, the osteoclasts resorb bone and the osteocytes, sometimes considered mature osteoblasts, are surrounded by bone tissue exerting regulatory functions on bone metabolism.

## Bone healing

In endochondral ossification the initially formed cartilage is later replaced by bone. In intramembranous ossification minerals are deposited directly into the connective tissue. The bone is continuously remodelling throughout life. It is adjusting to functional demands and consequently the turnover rate varies between different bones. The rate is high in the growing child and is slowing down with age.

In the bone healing process two major stages are identified, primary repair and secondary remodelling (Schenk et al 1994). Upon damage different cell types migrate into the wound and among them are stem cells. After removal of necrotic tissue by macrophages and giant cells various mediators are released to stimulate the process. Following in-growth of blood vessels a bone matrix is formed by the osteoblasts and the

matrix gradually becomes mineralised. The process is complex and not yet fully understood and both local and systemic factors affect bone formation and in the process both osteoblastic and osteoclastic activities are at play.

## **Bone grafting**

In bone grafting different mechanisms are working more or less in concert:

- new bone can be formed directly by surviving transplanted cells, which establish centres of bone formation. Cancellous bone and marrow grafts might provide such viable cells.
- osteoconduction occurs when dead bone or other porous materials passively guides the in-growth of new bone. Sometimes the implanted material is resorbed. This is a slow process and may take years depending on the size of the segment and the type of implanted material.
- osteoinduction is the phenotypic conversion of connective tissue into bone by appropriate stimulus. The bone morphogenetic proteins in the graft matrix can induce differentiation of undifferentiated mesenchymal cells in the host region into bone producing cells.

Local factors affecting bone formation include viability of the recipient bed, interface stability, amount and activity of growth factors such as BMPs.

Systemic factors of importance are age, gender, and somatic status such as diseases, drugs, and physical activity. With growing age the hormonal activity decreases and thus the turnover rate of bone is decreased. Hormones like calcitonin, growth hormone, insuline, estrogen, progesteron, glucocorticoids, thyroid hormone, and parathyroid hormone can influence the bone turnover and consequently the bone quality.

Bone grafts are frequently required in maxillofacial surgery procedures such as alveolar ridge augmentation, treatment of alveolar clefts and other defects as well as augmentation genioplasty. Defects in the adult facial skeleton caused by trauma, neoplasm, infection or congenital craniofacial deformities often require some kind of grafting procedure in order to replace lost bone, to stabilize the osseous segments and to

enhance healing. The development within the field of implant surgery has increased the demand for bone grafts. Recipient areas often do not have a bone volume large enough to harbour the implants and thus the volume has to be increased.

Considerable efforts have therefore been made to identify and investigate different bone substitute materials to be used in maxillofacial surgery.

However, the optimal grafting material is autogenous cancellous and cortical bone.

Cortical bone is preferred for defects that initially require a certain form and strength in reconstruction. Cancellous bone is preferred in limited defects such as alveolar clefts and will possibly provide more viable bone cells. Harvesting autogenous bone has disadvantages such as most often requiring a second surgical site, which can prolong the operation time and increase the morbidity. Moreover autogenous bone cannot always be provided in sufficient amount. Therefore efforts to find substitute materials are still ongoing.

## **Bone substitutes**

Ideally a bone substitute should

- be fully biocompatible
- actively stimulate new bone formation
- be able to serve as an anchoring surface for host cells
- have a structure that allows osteoconduction
- be progressively resorbed and replaced by new bone
- be strong
- be commercially available in sterile form

No such substitute exists today. However, a number of less ideal substitutes have been described throughout the years and used with varying rates of success. Different varieties of stainless steel were the first alloplastic materials to be used with success in orthopaedic surgery. Cold curing methyl methacrylate, silicon rubber, composite materials and degradable ceramics have also been introduced as bone substitute materials.

Substitutes for bone replacement can be classified according to their origin:

- Human                      Alloimplant i.e. demineralised bone
- Animal                      Xenoimplant i.e. deproteinised bone (BioOss) and coral (Alveograf<sup>®</sup>, Interpore 200<sup>®</sup>)
- Synthetic                    Calcium salts, glass ionomer cement, bioactive glass

The bone autograft remains the standard to which all substitute must be compared. Bone from another human, bone alloimplant, is sometimes commercially available in freeze-dried or deep-frozen form. It contains no viable cells and therefore the term implant and not graft is more appropriate. In xenoimplants antigens have been removed usually through a process of deproteinisation. Consequently the sustained immune response inherent in xenoimplants resulting in demarcation by a thick layer of fibrous tissue has been eliminated. The original porosities of the bone are maintained (Bio-Oss<sup>®</sup>) allowing for bone in-growth. Material from natural corals (Alveograf<sup>®</sup>, Interpore 200<sup>®</sup>) consists of tricalcium carbonate and through its porous structure human cells can invade the material. Another calcium salt is calcium sulfate also known as plaster of Paris. In the presence of water, it forms a moldable paste that will harden gradually. The material elicits a mild inflammatory response and is resorbed within 6 to 8 weeks.

The architectural structure and porosity of the ceramics have been considered important in facilitating interface activity with the host and potentiating bone in-growth. While the formation of large crystals and increased density promote long lasting stability it prevents in-growth of natural bone. Biodegradation allows the implant to be replaced with natural bone. A wide spectrum of ceramic biomaterials with different properties has been tried with focus on mechanical strength (Piecuch et al 1983, 1984, 1986, Beirne et al 1986, Block et al 1980). Through high temperature and pressure techniques different ceramics have been transformed into solid or porous forms of hydroxyapatite. This has been of particular interest due to its chemical and structural similarity to bone.

## **BMP and demineralised bone matrix**

The history of bone morphogenetic proteins (BMPs) began with the observation that demineralised bone matrix induced ectopic bone formation in subcutaneous and intramuscular pockets in rodents (Urist, 1965; Van de Putte & Urist, 1965). Urist described that demineralised lyophilised particles of bone had osteoinductive property, which he attributed to a bone morphogenetic protein (BMP) present in the demineralised bone matrix. A chemo sterilized bone preparation - autolyzed, antigen extracted and allogeneic bone (AAA-bone) - described by Urist (1975) preserves the BMP activity. As demineralised bone matrix related bone formation was observed to occur in ectopic sites, it was assumed that pluripotent mesenchymal cells were attracted to the site of implantation. Isolation of the bone-inducing substance revealed that certain proteins were responsible.

Since 1965 it has been demonstrated that BMP is not a single entity but that bone formation is induced by a number of bone morphogenetic substances (Rosen et al, 1989) working in concert.

BMPs belong to the transforming growth factor (TGF $\beta$ ) superfamily, which consists of a group of peptide growth factors. More than 40 related members of this family have been identified, including BMPs, growth and differentiation factors (GDFs), inhibins/activins, TGF $\beta$ s and Müllerian inhibiting substance (Massague 1990, Kingsley 1994, Reddi 1998). The cost of manufacturing the BMPs is often high which probably is why reports on their clinical use have been scarce and only a few are found in the literature (Glowacki et al 1981, 1984; Sailer et al 1994).

Since 1965 the bone induction process has attracted much attention. In a comparison between autogenous bone, AAA bone and deproteinised bone (in essence bone mineral) placed into bone cavities with thin walls, the AAA bone cavities were found to heal almost as well as those with bone autograft (Rosenquist et al 1982, Edwards JT et al 1998). Cartilage appears 5–10 days after implantation of active demineralised bone matrix (Sampath & Reddi 1983). The cartilage mineralises by day 7–14 and is subsequently replaced by bone. After 21 days, haematopoietic bone marrow formation can be observed (Reddi et al 1987; Wang 1993). The cellular events observed are similar to what is seen in embryonic bone development and normal fracture repair (Reddi & Huggins 1972).

Mature osteoblasts and fibroblasts could not be induced to express osteogenic parameters after treatment with BMP-2 (Katagiri et al 1990). These results indicate that the osteogenic influence of BMPs is directed towards immature and multipotent cells. Mature cells seem to lose their responsiveness. In healing fractures, which contain many immature cells, expression of native BMPs has been demonstrated (Bostrom et al 1995, Onishi et al 1998).

## **Reconstruction with dental implants**

Although utilization of titanium implants, as part of oral rehabilitation is not restricted to a certain age group a majority of the patients subjected to implant surgery are senior. This is at an age when the effect of osteoporosis is increasing particularly in women. In addition to bone loss due to osteoporosis the edentulous alveolar ridge undergoes different degree of resorption due to lack of or unfavourable loading. For the patient wearing removable dentures retention problems are therefore raising over time. Efforts, which have been made to restore the alveolar crest with autogenous bone graft, yield poor results because of rapid total resorption of the transplant. This might not withstand the forces of a new removable denture. Severe bone resorption can also be due to other local factors such as early loss of teeth and periodontal infections.

Before insertion of titanium fixtures in severely resorbed maxillas bone reconstruction is needed. If the need of bone is limited autogenous bone can be harvested from other sites nearby such as the mandibular ramus. However, if the need for bone is greater the iliac crest is usually chosen as donor site especially if no bone substitute is available. In the search for a bone substitute material, ceramics of solid or porous forms have been tried due to their resistance to resorption.

The osseointegration of titanium implants in partly resorbed alveolar bone could be increased with the addition of a bone inductive substitute such as AAA-bone. This has been shown in a study by Wang et al (1993) where the rate of osseointegration of threaded cylindrical uncoated titanium implants in edentulous dogs increased when BMP was added.



## Osteoporosis

Osteoporosis is a skeletal condition characterized by decreased density of normally mineralized bone (Glaser et al 1997). The reduced density impairs the mechanical strength causing fractures after a long latent period with no clinical signs. The World Health Organization (WHO) has classified osteoporosis into two categories, primary and secondary. Primary osteoporosis is further divided into three groups, postmenopausal, age-related and idiopathic. Secondary osteoporosis refers to patients in whom a causative factor or disease is known (WHO report 1994).

WHO has established diagnostic criteria for osteoporosis based on bone density measurements by dual-energy x-ray absorptiometry (DEXA). According to these criteria the diagnosis osteoporosis is made if a patients bone mineral density (BMD) is 2.5 standard deviations below the mean value for young normal people.

**Table 1. WHO's diagnostic criteria for osteoporosis**

BMD= bone mineral density, SD= standard deviation.

Group	Diagnostic criteria
Normal	BMD within 1 SD of reference value
Osteopenic	BMD 1-2.5 SD below reference value
Osteoporosis	BMD 2.5 SD or more below reference value
Severe osteoporosis	One or more fragility fractures

In women osteoporosis is related to menopause and is usually evident five years after its onset. Osteoporosis also affects the jaws (Rosenquist et al 1978, Habets et al 1988). Obviously the decrease in estrogen production occurring at menopause plays an important role in the development of osteoporosis. Through special receptors estrogen has a direct role in the early cell differentiation and also exerts a stimulatory effect on the mineralisation process. Moreover, estrogen has an inhibitory effect on prostaglandin synthesis (Monaghan et al 1992). Whether the decrease in estrogen production in elderly women explains an over-representation of these in patients with titanium implant losses is unknown. It could be that estrogen deficiency negatively affects bone healing.

## Handling of material

Surgeons using different bone grafts and bone substitute material must consider the limitations of the materials. The sterility of the graft or the implant must be maintained; heating or prolonged air and saline exposure must be avoided. Also an optimal host bed must be prepared for the graft or the implant. One of the important factors in bone healing is a good initial stability between the material and the recipient bone. Fibrin glue such as Tisseel® can therefore be useful in order to keep the implant material in position. If the implant material is in granular form mixing it with Tisseel® produces a paste, which facilitates the handling of the material. Tisseel® also has a haemostatic effect that could be advantageous. It acts through preventing and delaying fibrinolysis. The haemostatic effect on the wound minimises swelling and bleeding. The fibrin glue can also serve as a substrate for tissue in-growth and enhance bone formation (Arbes et al 1981, Kania et al 1998). However, its effects on the bone wound are unclear and the normal bone healing process could be delayed or otherwise negatively affected (Jarzem et al 1996; Turgut et al 1999). Jarzem et al (1996) showed in a study on spinal fusions in dogs that the fibrin sealant significantly retarded bone fusion when allograft was used. Turgut et al (1999) demonstrated that a local fibrin sealant significantly delayed the osteogenic fusion in a model of corticocancellous bone grafting in cats. They concluded that a fibrin sealant is not suitable for fixation of bone fragments in anterior cervical fusion. On the other hand Kania et al (1998) showed in a rabbit model that in tibial defects filled with coral granules and Tisseel significantly more bone was formed than when no Tisseel was used. They concluded that one explanation was that the coral granules were retained in the defect and therefore displacement was prevented. In a clinical trial with heterologous cancellous bone grafting Arbes et al (1981) showed that a fibrin sealant enhanced the remodelling of the graft to the extent that the use of a fibrin sealant was justified.

# Aims

The aims of this dissertation was to study

- bone healing when solid and porous hydroxyapatite with or without a fibrin sealant were placed into surgically created mandibular bone defects,
- bone-implant interface when hydroxyapatite granules were placed subperiostally in the mandible,
- bone healing when porous hydroxyapatite granules and blocks, alone or mixed with AAA bone granules, were placed into surgically made tibial bone defects,
- bone healing of surgically made tibial and calvarial bone defects with AAA bone granules in ovariectomized animals,
- stability and healing of titanium implants placed in AAA bone reconstructed tibial defects,
- the consequences of ovariectomy on the plasma content of estradiol, uterus weight and bone mineral density (BMD).

# Materials and Methods

The implant materials used in the present studies were commercially available solid granules (Alveograft®) and porous granules and blocks (Interpore 200®). The porous hydroxyapatite has an osteoconductive property in that it, through its pores, passively guides the in-growth of new bone. Thus the osteoinductive capacity of bone tissue is missing.

The osteoinductive capacity is obtained by using demineralised bone or autolyzed antigen extracted allogeneic bone (AAA). For all the experiments presented in the papers the AAA bone were produced locally in the laboratory. AAA bone was prepared as described by Urist 1965, by Reddi and Huggins 1972 with modifications described by Nishimoto 1985.

## AAA-bone preparation

Tibia, femur and humerus were removed from 4-month-old New Zealand White rabbits. The bones were cleaned of tendons and soft tissue and washed for 15 minutes in distilled water with continuous stirring. After 4 h in chloroform : methanol and 72 h in 0,1 M phosphate buffer the bones were dried over night.

The bones were crushed in a mill grinder. Bone granulas were sieved to obtain 70-400 µm pieces. The crude bone particles were demineralised three times in 0,5 M HCl for 3 h with continuous stirring followed by centrifugation for 10 minutes at 3000 rpm.

Demineralised bone granulas were then washed three times in distilled water by continuous stirring and centrifugation each for 30 minutes, three times in 95 % ethyl alcohol for 20 minutes and rinsed with ethyl ether in 30 minutes. The bone granulas were air dried over night.

Through the process the mineral content was reduced to 30 % of the original bone and this was controlled through measurement of ash weights before and after the process in a number of samples. Only granules with the size more than 70 microns and less than 400 microns were used.

## **Animals**

In study I, II and IV New Zealand White adult rabbits of both gender were used. In study III and V only adult female rabbits were used.

All animals were kept in their own cages and were fed a standard laboratory diet.

## **Specimen preparations and analysis.**

In study I the bone specimens were decalcified and sections of 7  $\mu\text{m}$  were stained with haematoxylin- eosin. A morphometric estimation of the ratio of soft/ bone tissue was made by a digitalisation technique.

In studies II, III and IV ground sections were prepared. In study II microradiographs from sections with the thickness of 80  $\mu\text{m}$  were made with a Siemens tube at 15 kV with the sections placed in direct contact with Kodak spectroscopic plates. In series 1, morphometric analysis of the sections was done by point sampling (Revell 1983). In series 2 the area of newly formed bone was calculated with a digitizing table ( Hipad digizer, Huoston Instrument, Huoston, TX,US).

In study III sections of 80  $\mu\text{m}$  microradiographs were analysed in pre-determinate areas and thereafter for light microscopy they were further grounded down to approximately 30  $\mu\text{m}$  for analysis of the fluorochrome labelling.

In study IV sections were grounded down to 10  $\mu\text{m}$  and the degree of bone-implant contact was measured in the two threads, which were situated in and just below the upper cortical layer.

In study V the bone specimens were decalcified and sections of 7  $\mu\text{m}$  were stained with haematoxylin- eosin. A morphometric estimation of the ratio of bone/soft tissue was made by a digitalisation technique.

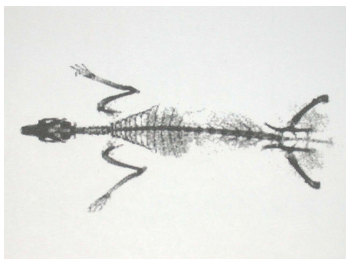
## **Blood**

Blood samples were obtained for estradiol analysis on two occasions, at the time of the insertion of AAA bone and at the time of sacrifice after twelve weeks. 2 ml blood was withdrawn each time from the marginal ear vein. The blood samples were allowed to clot and then centrifuged. The serum was stored frozen in glass tubes at  $-20^{\circ}\text{C}$ . The

estradiol concentration was measured on duplicates and on all samples at the same time using competitive immunoassay (Immulite® 2000 Estradiol, Diagnostic Products Corp., Los Angeles, US).

## Dual energy x-ray absorptiometry (DEXA)

14 of the animals, 7 control and 7 ovariectomized, were placed in a prone position and stored in  $-18^{\circ}\text{C}$ . In frozen condition the bone mineral density was measured through dual energy x-ray absorptiometry (Lunar DPX-L) with a small animal total body acquisition program for animal smaller than 5 kg. With a voltage of 70.0, current 150  $\mu\text{A}$ , fine collimation, sample size 1.2x2.4, sample interval 1/16, scan width 340 mm and scan length 700 mm. (Lunar DPX-L, Lunar corp., Madison, Wisconsin, US)



**Fig 1.** DEXA image protocol. Bone density expressed in  $\text{g}/\text{cm}^2$ .

## Fibrin glue

In all studies human biological glue (Tisseel®, Duo Quick, Immuno, Vienna, Austria) was used to make the implant material easier to handle and retain. The glue made from human blood contains fibrinogen, fibronectin, plasminogen, factor XIII, aprotinin and albumin as active substances, which are activated by adding thrombin and calcium resulting in a fibrin coagulum.

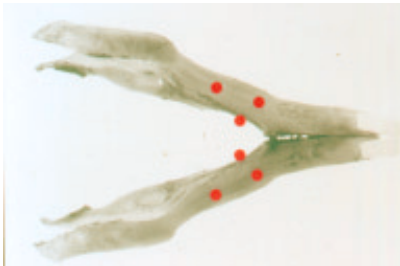


**Fig 2.** Tisseel<sup>®</sup>, Duo Quick, a two component glue.

The methods used in these studies are described in detail in respective papers. A brief summary of each follows:

## **Paper I.**

Implantation of hydroxyapatite granules in standardized quantity was made with or without Tisseel<sup>®</sup> into standardized cavities in the mandible in adult 12 rabbits (Fig 3).



**Fig 3.** Sites for implantation of hydroxyapatite granules in bone and on bone surface.

Two types of hydroxyapatite granules were studied. Alveograf<sup>®</sup> consists of solid granules of durapatite with a particle size of 500- 1200 microns and Interpore 200<sup>®</sup> consists of hydroxyapatite with the same granule size but with porosities of 200 microns in size.

Standardised amounts of the material were placed in preformed defects, 3 mm in diameter, in the mandibular base and also subperiostally on the medial mandibular bone surface.

The healing time was six month and 7 µm sections were made of specimens from the implanted sites. A morphometric estimation of the ratio soft /bone tissue in the defects was made by a digitalisation technique.

## Paper II

The study consists of two series. The experimental sites were the mandible base border (**series I**) and the medial part of the proximal tibia bone (**series I and II**) of healthy rabbits.

**In series I**, comprising 12 adult rabbits hydroxyapatite in granular form was studied.

**In series II**, comprising 14 animals, hydroxyapatite in block form was used.

AAA bone was prepared as described above by Urist et al and modified by Nishimoto et al. The mineral content was in this way reduced to 30 % of the original content and this was controlled through measurement of ash weights before and after the process in a number of samples. Only granules with the size more than 70 microns and less than 400 microns were used.

Hydroxyapatite commercially available as granules (series I) and blocks (series II) was used (Interpore 200®).

The observation time was in **series I** 5 weeks and in **series II** 8 weeks.

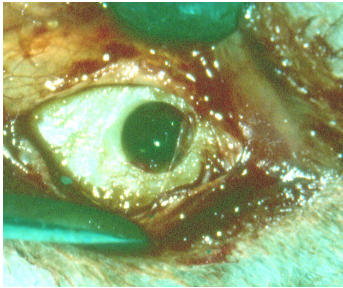
Tisseel®, fibrin glue, was added allotted to the implant material for half of the cavities.

### **In series I**

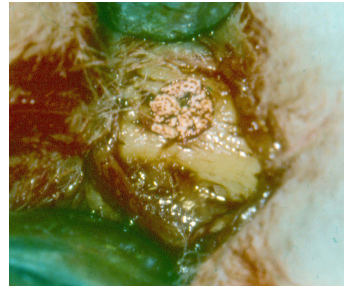six implant combinations were used:

- 1) Interpore 200 alone,
- 2) Interpore 200 in combination with a fibrin glue Tisseel,
- 3) AAA bone alone,
- 4) AAA bone in combination with a fibrin glue Tisseel,
- 5) Interpore 200 in combination with bone granulas (AAA bone),
- 6) Interpore 200 in combination with bone granulas (AAA bone) and a fibrin glue Tisseel.





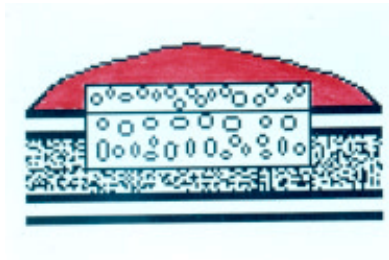**Fig 4** Surgical defect in the tibia



**Fig 5** Defect filled with granules

## **In series II**

6x3 mm blocks of hydroxyapatite were placed in surgically made cavities in the medial proximal tibia measuring the same size and extending outside the cavity by 2 mm (Fig 6). Half of the blocks were covered with paste containing of AAA bone and Tisseel ® and the other half were covered with Tisseel ® alone.



**Fig 6** Block of hydroxyapatite in tibia defect covered with AAA bone (red colour)

**In series I**, sections from specimens were studied in light microscope and morphometric analysis of the relationship between bone, soft tissue and hydroxyapatite in the cavities were made by point sampling according to Revell 1983. The amount of bone was calculated and expressed as percentage of the defect space available for bone formation.

**In series II**, photographs of microradiographs were studied. The amount of bone formed outside the normal bone contour was calculated with a digitising table in conjunction with a computer. The area of newly formed bone was calculated in percentage of the area of the hydroxyapatite block, which extended outside the bone surface.

## Paper III

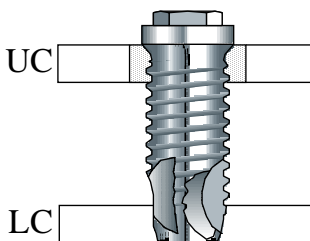
Of a total of 17 female rabbits 9 were made estrogen deficient through surgical removal of the ovaries four weeks prior to start of the bone experiment. The rest were sham operated. Standardized round cavities, 5 mm in diameter, were made in the medial part of each proximal tibia. To half of the cavities standardised amounts of AAA bone, made in the laboratory, were added together with Tisseel® and the other half were filled with Tisseel® only. At the end of the study microradiograph and ground sections were made and analysed. The bone and non-bone areas in selected region/area were measured. The percentage of bone tissue was calculated for each section.

## Paper IV

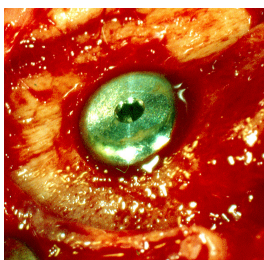
18 adult New Zealand White rabbits were used in the study.

Experimental defects, 5 mm in size, in the medial proximal tibia were reconstructed with AAA bone. After four weeks of healing the experimental bone areas was exposed. The earlier defects could easily be identified due to a dark appearance of the newly formed bone. An implant site for a 10 mm long implant was prepared in the center of each defect by using a series of drills; 1.8 mm round drill, followed by 2 and 3 mm twist drills. No countersink drill was used.

Figure 7 is showing the implant placement in tibial bone. The implant was inserted in the centre of the defect area through the two cortical bone layers. UC: upper cortex. LC: lower cortex. Hatched area: reconstructed with AAA bone.



**Fig 7.** Titanium implant inserted in tibia bone.



**Fig 8.** Fixture implanted in tibia.

After healing implant stability was measured with frequency resonance analysis. The resonance frequency (Hz) of the transducer detected as a peak in an amplitude-frequency plot was used to describe implant stability. Measurements were made with the transducer beam perpendicular and parallel to the tibia.

Sections were ground to a thickness of about 10  $\mu\text{m}$  and stained with 1% toluidine blue and 1% pyronin-G. The sections were viewed in a Leitz Orthoplan microscope equipped with a Leitz Microvid Morphometric System connected to a PC. With this system morphometric measurements could be carried out directly in the microscope. The degree of bone-implant contacts was measured in the first two threads, which were situated in and just below the upper cortical layer and the interface between implant and bone was studied.

## Paper V

Out of a total of 38 female rabbits 19 were made estrogen deficient through surgical removal of the ovaries four weeks prior to the start of the bone experiment. The rest were sham operated. Two round cavities, 4 mm in diameter, were made in the cranial skull bone one on each side of the midline and 5 mm round cavities were made on each medial side of proximal tibia. To half of the cavities AAA bone and Tisseel<sup>®</sup> were added and the other half were left to heal with only Tisseel<sup>®</sup>. Blood sample were taken at two times for measurement of the estradiol level in serum. The first time 4 weeks after ovariectomy and the second time at the end of the study 12 weeks later.

The animals were sacrificed 12 weeks after bone surgery and the uteri were dissected free, wrapped in plastic and frozen. They were later weighed using a laboratory balance. The area of each bone cavity with surrounding bone was carefully excised en bloc and immediately frozen in isopentane and stored at -70°C. Sections were made and the bone and non-bone areas in selected region/area were measured. The percentage of bone tissue was calculated for each section.

The bone mineral density was measured through dual energy X-ray absorptiometry (DEXA), (Lunar DPX-L, Lunar corp., Madison, Wisconsin, US) using a small animal total body acquisition program for animal smaller than 5 kg. With the following settings: a voltage of 70.0, current 150 µA, fine collimation, sample size 1.2x2.4, sample interval 1/16, scan width 340 mm and scan length 700 mm.

Blood samples were obtained for estradiol analysis on two occasions, at the time of the insertion of AAA bone after four weeks and at the time of sacrifice after sixteen weeks. Each time 2 ml blood was drawn from the marginal ear vein. The blood samples were allowed to clot and then centrifuged. The serum was stored frozen in glass tubes at -20 °C. The estradiol concentration was measured in duplicates and on all samples at the same time using competitive immunoassay (Immulite® 2000 Estradiol, Diagnostic Products Corp., Los Angeles, US).

## **Statistics**

A Statistical package (SPSS 11.5, SPSS Inc., Chicago, Illinois, USA) was used for the analyses. The mean and standard deviation values for each measured parameter were used in all studies. Wilcoxon's matched pairs signed rank test was used for paired analyses between control and experimental sites. The level of significance was set to  $p < 0.05$ .

# Results

## **Combined use of hydroxyapatite and Tisseel® in experimental bone defects in the rabbit. (Paper I)**

Microscopically examination revealed that most of the hydroxyapatite granules located within the bony defects were surrounded by trabecular bone tissue. No differences were observed regarding in-growth of bone tissue between the group with solid hydroxyapatite granules (Alveograf®) and those with porous granules (Interpore 200®). The addition of a fibrin sealant Tisseel® did not seem to either improve or inhibit bone healing. Regarding the subperiostally implanted hydroxyapatite granules no signs of resorption of the underlying bone tissue were seen. The soft tissue surrounding the implants consisted of dense fibrous tissue with few signs of inflammation.

**Table 2. Morphometric estimation of the percent soft tissue of experimental area implants excluded.**

Combinations	Mean value%	Standard deviation
Alveograf	24.3	16.6
Interpore 200	24.5	19.0
Alveograf/Tisseel	19.6	15.3
Interpore 200/Tisseel	20.4	15.8

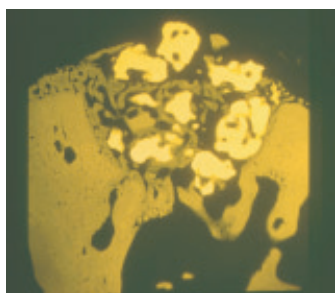
## **Bone healing after implantation of hydroxyapatite granules and blocks (Interpore 200<sup>®</sup>) combined with autolyzed antigen-extracted allogeneic bone and fibrin glue. (Paper II)**

The bone formation was not negatively affected by the addition of a fibrin glue and the results were therefore calculated regardless of this addition and the groups were consequently reduced to three in series I. The combination of AAA bone and hydroxyapatite stimulated bone formation (Fig 9 and 10) more than any other combination ( $p < 0.005$ ).

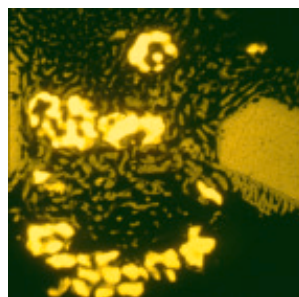
### **Series I**

**Table 3. The amount of new bone expressed as per cent of experimental area implants excluded.**

<b>Combinations</b>	<b>Amount of bone</b>	<b>Standard deviation</b>
Hydroxyapatite	60.3	10.9
Hydroxyapatite/AAA	66.4	12.5
AAA	62.7	14.6



**Fig 9.** Hydroxyapatite (HA) granules In mandibular defect(1:1)



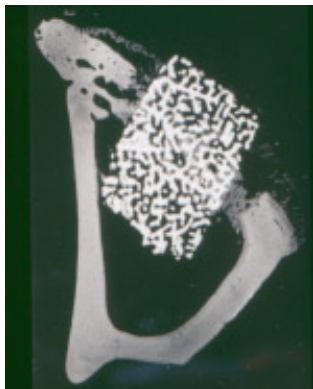
**Fig 10.** HA granules in tibial bone defect with AAA bone added(1:1)

## Series II

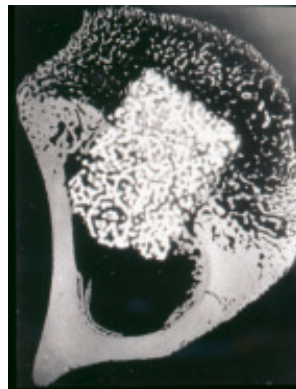
In series II the bone formation was excessive around blocks combined with AAA bone. When the periosteal side of the block was covered by bone, bone was also formed throughout the block (Fig 11 and 12).

**Table 4. The amount of new bone tissue expressed as per cent of the area exceeding the normal bone contour.**

Combinations	Amount of bone	Standard deviation
Blocks with AAA bone	44.9	5.3
Blocks alone	16.8	3.6



**Fig 11.** Hydroxyapatite block in tibia (1:1).



**Fig 12.** When AAA bone was added to the block new bone was formed throughout the entire block porosities(1:1).

## Bone formation after implantation of autolyzed antigen extracted allogeneic bone in ovariectomized rabbits. (Paper III)

No significant differences in bone healing were found between the ovariectomized animals and the controls. When AAA bone was added to the bone defects the bone formation was considerably enhanced. This was observed to a slightly lesser degree in the ovariectomized animals than in the controls.

**Table 5. Percent bone volume per specified area of interest**

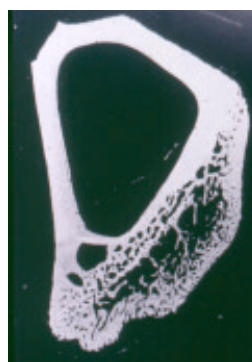
Group	Mean value	Standard deviation
Ovariectomized	29.3	6.6
Control	34.6	11.1
Ovariectomized /AAA	42.3 <b>b</b>	13.5
Control/AAA	55.5 <b>a</b>	12.2

**a/** significantly different ( $p < 0.001$ ) from all other groups.

**b/** significantly different ( $p < 0.005$ ) from the ovariectomized group when no AAA bone was added.

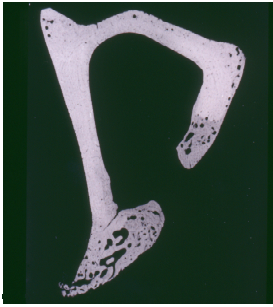

**Fig 13.** Healing of defect in control group(1:1).

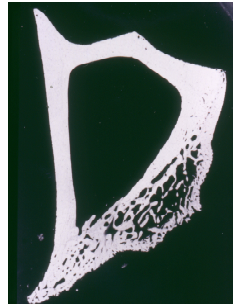


**Fig 14.** Healing of defect filled with AAA bone(1:1).





**Fig 15.** Healing of defect  
In experimental group(1:1).



**Fig 16.** Healing of defect  
filled with AAA bone(1:1).

Some of the defects did not heal completely although the defects were not of critical sizes (Fig 15). All defects healed when AAA bone was added and excessive bone formation was often observed (Fig 16).

**Integration of titanium implants in bone defects reconstructed with autolyzed antigen extracted allogeneic (AAA) bone powder prior to implant placement.**

**A histological and resonance frequency analysis study in the rabbit.**

**(Paper IV)**

Although the study showed a significant increase in percent bone to implant contact no difference were seen in implant stability. This could be explained by the fact that the newly formed bone around implants where AAA bone was used had a more immature appearance and therefore were softer. At the time when the bone has matured to a more lamellar type the stability would probably increase.

**Table 6. Results from RFA and morphometric measurements (BIC= bone implant contact) in the three groups.**

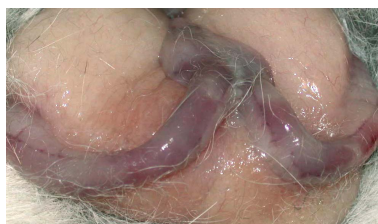
<b>Group 1</b>	<b>Defect +AAA bone</b>	<b>Defect</b>	<b>Statistics</b>
<b>RFA (Hz)</b>	7988 $\pm$ 406	7984 $\pm$ 326	Ns
<b>BIC (%)</b>	68.1 $\pm$ 9.8	55.8 $\pm$ 8.6	p = 0.027
<b>Group 2</b>	<b>Defect + AAA bone</b>	<b>No defect</b>	<b>Statistics</b>
<b>RFA (Hz)</b>	8237 $\pm$ 479	8525 $\pm$ 434	ns
<b>BIC (%)</b>	62.7 $\pm$ 9.0	52.9 $\pm$ 3.1	p = 0.043
<b>Group 3</b>	<b>Defect</b>	<b>No defect</b>	<b>Statistics</b>
<b>RFA (Hz)</b>	8626 $\pm$ 508	8031 $\pm$ 621	Ns
<b>BIC (%)</b>	54.4 $\pm$ 7.3	54.8 $\pm$ 8.9	Ns

## Healing of bone defects in osteopenic rabbits.

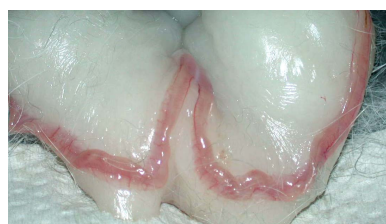
### Effect of autolyzed antigen extracted allogeneic bone substitute on calvarial and tibial bone.

#### (Paper V)

A dramatic consequence of the ovariectomy was the decrease in uterus weight by 64 %, from 7.4 g in the control animals to 2.7 g in the ovariectomized animals.



**Fig 17.** Uterus in control animal



**Fig 18.** Uterus in ovariectomized animal

Analyze of estradiol concentration from blood plasma samples revealed significant difference between the control and experimental groups ( $p < 0.05$ ). There was also a significant decrease of the estradiol level in the experimental group by time (24 %). The body mineral density (BMD) measurement was made 112 days after ovariectomy and the decrease of the BMD was 7 % and significant ( $p < 0.003$ ).

**Table 7. Body weight, uterus weight, serum estradiol and bone mineral density.**  
**Mean values and standard deviations**

Parameter	Control group	Experimental group
Body weight, initial, kg	$3.8 \pm 0.5$	$3.7 \pm 0.5$
Body weight, final, kg	$4.3 \pm 0.5$	$3.9 \pm 0.6$
Uterus weight, g	$7.4 \pm 1.7$	$2.7 \pm 1.8$
S-estradiol, initial, pmol/l	$185.5 \pm 12.4$	$154.4 \pm 8.6$
S-estradiol, final, pmol/l	$182.5 \pm 9.7$	$139.1 \pm 7.1$
Bone mineral density, whole body, $\text{g/cm}^2$ (DEXA)	$0.522 \pm 0.017$	$0.486 \pm 0.004$

**Table 8. Percent bone volume per specified area of interest in tibial bone**

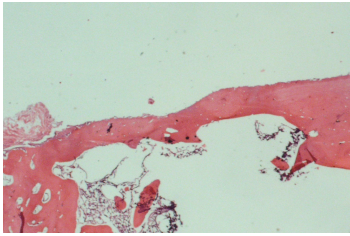
<b>Group</b>	<b>Mean value</b>	<b>Standard deviation</b>
Ovariectomized	54	2.2
Control	51.5	2.7
Ovariectomized /AAA	57.4 <b>a</b>	1.4
Control/AAA	55.4 <b>b</b>	1.7

A significant higher bone volume in the tibia was seen when AAA bone was added in both the ovariectomized **a** ( $p<0.001$ ) and in the control **b** ( $p<0.02$ ) group.

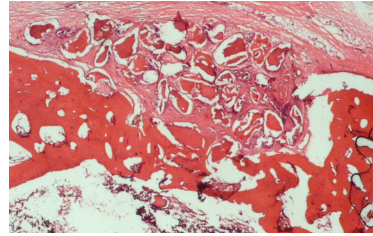
**Table 9. Percent bone volume per specified area of interest in calvarial bone**

<b>Group</b>	<b>Mean value</b>	<b>Standard deviation</b>
Ovariectomized	40.9	11.6
Control	42.5	5.6
Ovariectomized /AAA	52 <b>a</b>	6.8
Control/AAA	51.4 <b>b</b>	7.2

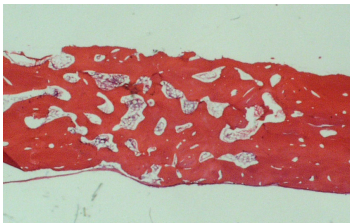
A significant higher bone volume in the calvarial bone was seen when AAA bone was added in both the ovariectomized **a** ( $p<0.005$ ) and in the control **b** ( $p<0.005$ ) group.



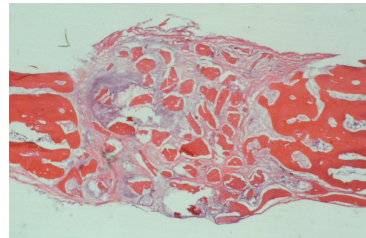
**Fig 17.** Tibial healing without AAA  
(htx+eosin x 10)



**Fig 18.** Tibial healing with AAA  
(htx+eosin x 10)



**Fig 19.** Calvarial healing without AAA  
(htx+eosin x 10)



**Fig 20.** Calvarial healing with AAA  
(htx+eosin x 10)

In tibia most of the defects healed in a similar fashion (Fig17) and with AAA bone the bone healing was enhanced (Fig 18). The same was seen in the calvarium (Fig 19 and 20).

# Discussion

## Research animals

The experimental bone healing studies were all performed on adult rabbits to allow for adequate precision in the sampling and preparation of bone specimens, which requires laboratory animals of sufficient size. In contrast to the rat the bone morphology of the rabbit is similar to human bone with a cortical covering layer, an inner structure of cancellous bone and a Haversian system. This makes examinations easier. The metabolic activity of the rabbit as compared to Man makes a short period of investigation sufficient to assess the degree of healing.

This animal model also ensured a low morbidity for the animal with easy access to chosen surgical fields. The location was such that the animal's access to the operation wounds was minimised. Initially (study I and II) the lower border of the mandible was chosen as the implant site. This bone is familiar to a maxillofacial surgeon. However, the rabbit mandible has a limited bone volume due to the presence of the large incisor tooth buds. Therefore the tibia and calvarium were selected for the further studies (study II, III, IV, V).

## Observation times

Different observation times were chosen so that bone healing could be studied in different time perspectives. In study I the bone healing was evaluated after a long period of time (6 months) and in study II (5 and 8 weeks), III (6 weeks), IV (4+4 weeks) and V (12 weeks) over shorter periods of time. In study I no osteoinductive effect was anticipated and in order for the incorporation of the implant to occur through osteoconduction a sufficiently long observation period was chosen. In study II bone healing was studied in the short term with a five-week observation time when granules were used and an eight-week period when porous blocks were used. Studies III and V were conducted on ovariectomized animals. It could seem rather obscure that six weeks were chosen for short-term observations and not five weeks as in study II. However, practical circumstances sometimes demand such alterations. The twelve-week period in

study V was chosen for medium long observations. When planning study IV earlier experiments (Sennerby, 1996) indicated that four weeks would be sufficient for enough bone to be formed to harbour implants. The four-week healing period after implant insertion was based on the experience that this period would be long enough for bone to form along the implants (Sennerby, 1996). However, in retrospect a slightly longer period might have yielded a more solid integration of the implants.

The size of the experimental defects, 3 – 5 mm in diameter, or 6x3 mm when hydroxyapatite blocks were studied, was chosen so as to limit the morbidity and not to a great extent interfere with the tooth buds or weaken the bone. They were smaller than critical size defects, which do not heal and which are commonly used in studies of materials (Glowacki et al 1981; Urist et al 1987, Ripamonti U 1992, Ripamonti et al 1989). Defects of the size chosen heal spontaneously themselves.

## **Implant materials**

Of all commercially available bone substitutes calcium phosphate compounds especially in the form of hydroxyapatite is of most interest because of the resemblance to bone mineral. Hydroxyapatite appears commercially in different forms and shapes. In granular and block forms it can be manufactured synthetically or from corals. Hydroxyapatite in its different forms does not elicit any foreign body reaction and has an osteoconductive property in that it can guide the in-growth of bone through the presence of pores. Calcium phosphate cements (CPCs) are composed of solid and liquid components which when mixed in predetermined proportions react to form hydroxyapatite (Schmitz et al 1999). Initially the mixture is mouldable and can therefore be well adapted to most recipient sites. Up to date the use of CPCs has only been reported anecdotally (Schmitz et al 1999). It was not available at the time when the present series of studies was commenced. Therefore, hydroxyapatite in solid (Alveograf®) and porous (Interpore 200®) granular forms has been used in the studies. Also porous hydroxyapatite in blocks (Interpore 200®) has been studied.

As hydroxyapatite lacks the ability to induce bone formation a substance or preparation with such property must be added in order to stimulate bone formation. Biosynthetically produced bone-inducing factors are expensive and scarcely available. Moreover these factors work in concert and in proportions yet unknown. Therefore, autolyzed antigen extracted allogeneic bone (AAA) was chosen as this has the ability to stimulate bone

formation through the local factors present in bone matrix. The AAA bone was prepared according to Urist (1975) modified by Nishimoto (1985).

**Table 10. A brief outline of the preparation of AAA-bone**

Step/Method	Urist	Nishimoto	Öberg
Removal of antigens: extraction of lipids, lipoproteins	4 hrs in chloroform: methanol 1:1, room temperature	3 x 15 min in 95 % ethanol	4 hrs in chloroform: methanol 1:1, room temperature
BMP preservation and chemo sterilisation	72 hrs in 0.1 M phosphate buffer pH 7.4 containing 10 millimoles/liter iodoacetic acid and 10 millimol/liter sodium azide, 37°C	-	72 hrs in 0.1 M phosphate buffer pH 7.4 containing 10 millimoles/liter iodoacetic acid and 10 millimol/liter sodium azide, 37°C
Particulation	100 - 5,000 µm	74 – 420 µm	70 - 400 µm
Demineralisation and extraction of acid soluble proteins	24 hrs 0.6 M HCl in 4 °C	3 x 1 hrs 0.5 M HCl with continuous stirring followed by centrifugation for 10 min at 3,000 rpm	3 hrs 0.5 M HCl with continuous stirring followed by centrifugation for 10 min at 3,000 rpm
Washing	-	3 times in distilled water followed by centrifugation for 10 min at 3,000 rpm 3 times in 95 % ethanol for 20 min and rinsed with ether	3 times in distilled water followed by centrifugation for 10 min at 3,000 rpm 3 times in 95 % ethanol for 20 min and rinsed with ether
Drying	24 hrs freeze-drying at -72 °C	Overnight air-drying at room temperature	Overnight air-drying at room temperature

Through the preparation procedure antigens were removed as even if bone has a relatively low antigenicity it contains enough antigens to elicit a host-versus-graft response. This has a negative impact on bone induction and formation. In our studies we followed Urist's original recipe for antigen removal using chloroform: methanol instead of ethanol and we also included BMP preservation step omitted by Nishimoto. We did so because we did not want to compromise the preparation as the experimental basis for these steps has been well documented (Urist et al, 1975). We did not follow the protocol with regard to particulation.



Urist et al showed that particles below the size of 400 µm elicit an inflammatory reaction obliterating the formation of new bone, a consequence we did not see. Compared with whole bone matrix particulated bone showed less inflammatory response (Urist et al 1975).

The bone used was prepared from young adult rabbits, as ageing individuals do not provide AAA bone of necessary quality (Nishimoto, 1985). For the preparation different tubular bones were pooled disregarding the suggestion that there is a slight difference in osteogenic potential between demineralised bone matrixes of different embryonic origin (Isaksson, 1992) as this was not supported by his data.

The amount of BMPs per volume bone in growing cortical skeleton is high and decreases with age. Most of the AAA bone prepared was of cortical origin. Prior to demineralisation the bones were particulated to a particle size between 70 and 400 µm. It has been demonstrated that smaller particles have limited osteoinductive power and particles larger than 400 µm are difficult to properly place in small bone defects (Nishimoto 1985). Demineralisation is necessary to expose the BMPs and this is particularly true for cortical bone with its higher content of minerals. However, it is very important after demineralisation to remove any residual HCl with repeated rinsing in sterile water, saline or neutral phosphate buffer. In Urist's description of the method (1975) this step has not been mentioned. In all studies the AAA bone was prepared in our own laboratory immediately prior to the experiment.

In the procedure used for preparing AAA bone the mineral content was maintained at 30 % of the original content. Most of the BMPs were thereby exposed and yet some stability of the material was kept. Therefore both bone resorption and induction probably got a fast onset. Consequently in studies II, III, IV and V no residual AAA bone material was seen in any histological sections.

## **Fibrin glue**

In study I it became apparent that hydroxyapatite granules are difficult to retain in defects as well as subperiostally. When fibrin glue, Tisseel ®, was mixed with the implant material the handling became much easier. Clinically Tisseel ® prevents postoperative bleeding and swelling but can also slow down the healing process, which may increase

the risk of infection. In the studies there were no infections and Tisseel ® did not seem to affect bone healing in study II and I. Therefore it was throughout the studies.

## **Preparation of sections for histological analysis**

In study I the bone specimens were decalcified and stained. Although considerable time was allowed for the chemical removal of mineral when cutting the specimens residual hydroxyapatite sometimes damaged the sections. Therefore in studies II, III and IV ground sections were prepared. For microradiographs these were 80 µm and for light microscopy they were further ground to approximately 30 µm (III) and 10 µm (IV). Finally in study V decalcified sections were prepared as no hydroxyapatite was implanted. Therefore routine laboratory procedures could be used. In order to demonstrate bone formation tetracycline was used to label bone (III). However, the attempt to measure the labelled areas and surfaces was aborted because of difficulties of interpretation.

## **Morphometrics**

A digitising technique was used for morphometric analyses. When the area of bone formation was calculated the area occupied by the implant material was excluded. In contrast to other reports (i.e. Holmes et al, 1988) it could be argued that the space occupied by implant material such as hydroxyapatite, which undergoes virtually no resorption, cannot be filled with new bone. Consequently, in calculations such as this, hydroxyapatite is at a disadvantage. In study I the amount of soft tissue in the regenerated areas of the bone defects was expressed as per cent of the total area. In studies II, III and V, the amount of newly formed bone was measured as focus was on bone formation induced by AAA bone. In study IV the degree of bone/implant contact was of major interest as this was anticipated to have a bearing on implant stability.

## **Implant stability**

Implant stability can be evaluated by torque measurements but this technique damages the specimens and renders morphological study impossible. Therefore resonance frequency analysis (RFA) was carried out in study IV. This was done in two directions, perpendicular and parallel to the tibial bone. A strong correlation between implant stability

and resonance frequency amplitude has been demonstrated (Meredith, 1996). In study IV implants were inserted in the tibia in normal bone, in a spontaneously healed bone defects and in defects reconstructed with AAA-bone. Despite a larger bone-implant area in the latter there were no differences in implant stability between the groups. This was probably due to a less mature and more cellular bone in the AAA defects. With increasing observation time it is not unlikely that the stability would be superior in such defects.

## **Experimental osteopenia**

Experimental osteopenia can be achieved through a calcium deficient diet, disuse or ovariectomy. The latter was chosen, as it is similar to the human situation and controllable as the consequential change in circulating estrogen could be measured. Estradiol is the major form of circulating estrogen and the concentration in blood plasma was measured on two occasions: four and twelve weeks after ovariectomy (study V). Already after 4 weeks the ovariectomy caused a drop in circulating estradiol by 16.8 %, which after another 12 weeks had decreased further to 23.8 % when compared with the sham operated rabbits.

Another direct consequence of ovariectomy was a decrease in uterus weight. At the time of sacrifice the uteri were dissected free, wrapped in plastic and frozen. The uterus weight had decreased by 63.5 % when the two groups were compared. In a study on rats with the same observation time the decrease was as much as 80.8 % (Kuroda et al, 2003). The difference is probably species dependent.

It was anticipated that ovariectomy should have an effect on bone density. Therefore, this was measured with dual energy x-ray absorptiometry (DEXA). A computer program designed for small animals (small animal total body acquisition) was used. Each measurement took approximately one hour with a sample size of 1.2 mm and a sample interval of 2.4 mm. Sixteen weeks after ovariectomy the total bone mineral density (BMD) had decreased by 6.9 %. This comparatively small change corroborates the view that osteoporosis is a multifactor condition.

Kuroda et al (2003) applied the DEXA technique on dissected mandibles and femora and could only disclose a difference in the femur. However, applying a more detailing method, avoiding the mandibular tooth buds, they found a general loss of trabecular bone of 12,5 % in rats after ovariectomy after 109 days, which is a long observation time.

## Hydroxyapatite and AAA-bone

In maxillo-facial surgery augmentation of resorbed alveolar ridges is often required to facilitate prosthetic rehabilitation through improvement of denture stability and retention. Hydroxyapatite was a popular choice of material for this purpose. It had been reported (Jarcho et al, 1977, 1981; Kay et al, 1978) that cement like structure was binding the hydroxyapatite to bone. It was unclear whether hydroxyapatite used for augmentation became attached to the bone surface through in-growth of bone or if the bone surface adjacent to the material was in any way affected. Study I showed that subperiostally placed hydroxyapatite was not incorporated into or even attached to the bone surface other than through a dense connective tissue. The osteoconductive property attributed to porous hydroxyapatite was not at play when the material was not placed within a bone cavity. However, there did not seem to be any resorption on the bone surface bearing in mind that the area was not loaded.

Porous hydroxyapatite placed within bone cavities becomes surrounded by trabecular bone and possibly also invaded by it through the process of osteoconduction. As a mean to improve the incorporation into bone tissue, hydroxyapatite was mixed with a material known for its osteoinductive property, AAA-bone, in study II. In the mixture hydroxyapatite might provide stability and maintain shape. Hydroxyapatite blocks were placed in bone cavities in an augmentative way, extending outside the normal bone contour. When no AAA bone was added there was an in-growth of bone into the block corresponding to the normal bone size. However, when covered with AAA bone the entire block was filled with new bone, which sometimes also extended outside the block surface. Similar results have been achieved when autogenous bone has been mixed with hydroxyapatite (Finn et al, 1980; Kent et al, 1983). The observation times (studies II - V) were too short for the bone to be able to mature. However, as anticipated there were no traces of any substance resembling AAA-bone, as this is easily resorbed, simultaneously releasing the bone morphogenetic factors.

## **Bone healing and estrogen deficiency**

The increasing demand for bone substitutes in oral and maxillofacial surgery is more obvious in elderly patients with severe resorption of the alveolar process. This situation is troublesome particularly when implants are to be inserted. Many factors influence the resorption of the alveolar process. Disuse due to long standing edentulousness is one important factor but systemic factors associated with osteoporosis play a part. One such is the decrease in estrogen production after menopause. Experimental osteopenia induced through a calcium deficient diet or tooth extraction (disuse) does not seem to impair bone healing in rats (Lundgren & Rosenquist, 1992; Rosenquist & Lundgren, 1992). The same was true for ovariectomy in rabbits, which caused a significant drop in circulating estradiol and BMD (study V). Tibial and calvarial bone cavities healed in the same fashion regardless of the presence of ovaries (studies III and V). The healing was considerably improved when the cavities were filled with AAA bone. This indicates that AAA bone could be useful asset in the clinic together with a bone substitute also in estrogen deficient patients. The most obvious consequence of ovariectomy (study V) was the considerable decrease in the weight of the uterus, which indicates that the reproductive organ is the main target for the sex hormone.

# Conclusions

- Hydroxyapatite granules, solid or porous in form, were biocompatible and were well incorporated in the bone. The addition of a fibrin sealant (Tisseel®) did not seem to interfere with bone regeneration.
- Hydroxyapatite granules placed subperiostally did not stimulate bone formation and did not induce bone resorption. The granules were not surrounded by bone but by fibrous tissue.
- The addition of AAA bone enhanced the bone formation and the hydroxyapatite implants were incorporated into newly formed bone.
- Ovariectomy and the consequent decrease in circulating estradiol did not inhibit the stimulatory effect of AAA bone on the healing of experimental bone defects with no difference between the tibia and the calvarium.
- The stability of implants inserted into areas previously reconstructed with AAA bone was found to be equal to implant inserted in normal bone. The bone-implant contact was significantly higher when AAA bone was used.
- Ovariectomy had a significant effect on uterus weight, concentration of estradiol in serum and bone mineral density.

# Acknowledgements

I wish to express my sincere gratitude to all who have supported me in this work with special thanks to:

Professor **Jan Rosenquist**, my supervisor, who introduced me to the research field of bone substitute materials, for sharing his great knowledge with me, for his help and encouragement.

Professor **Stefan Lundgren**, for his generous support and constructive discussions throughout the years.

Professor **Lars Sennerby**, Department of Biomaterial Science, Gothenburg University, for his assistants and his support as co-author.

Professor **Karl-Erik Kahnberg**, for introducing me to the laboratory work and his support as co-author.

**Monica Gordh**, for her generous support and collaboration as companion and co-author.

**Carina Johansson**, Department of Biomaterial Science, Gothenburg University, for her generous assistant and as co-author.

Laboratory assistants **Ingegerd Sandström** and **Lisbeth Lindberg**, for their assistances in handling of animals and preparation of bone specimens.

All colleagues and friends at the Department of Oral & Maxillofacial Surgery, Umeå.

My wife **Gunni** for supporting, loving and encouraging me throughout the years.

The faculty of Medicine-Odontology, Umeå University, the Swedish Dental Society for financial support.

# References

1. Alberius P, Isaksson S, Klinge B, Jönsson J, Sjögren S. Regeneration of cranial suture and bone plate lesions in rabbits. *J Cranio-Max-Fac Surg*. 1990;18:271-279.
2. Amsel S, Maniatis A, Tavassoli M, Crosby WH. The significance of intramedullary cancellous bone formation in the repair of bone marrow tissue. *Anatomical Record* 1969;164:101-111.
3. Arbes H, Bösch P, Lintner F, Salzer M. First clinical experience with heterologous cancellous bone grafting combined with the fibrin adhesive system (F.A.S.). *Arch Orthop Trauma Surg* 1981;98:183-188.
4. Aspenberg P, Lohmander LS, Thorngren K-G. Failure of bone induction by bone matrix in adult monkeys. *J Bone Joint Surg* 1988;70-B:625-627.
5. Babson AL. The IMMULITE automated immunoassay system. *J Clin Immunoassay* 1991;14:83-88.
6. Babson AL, Olson DR, Palmieri T, Ross AF, Becker DM, Mulqueen PJ. The IMMULITE assay tube: A new approach to heterogenous ligand assay. *Clin Chem* 1991;37:1521-1522.
7. Beirne O R, Curtis T A & Greenspan J S. Mandibular augmentation with hydroxyapatite. *J Prosthet Dent* 1986;55:362-367.
8. Bergquist C, Nillius SJ, Wide L. Human gonadotropin therapy: Serum estradiol and progesterone pattern during conceptual cycles. *Fertil Steril* 1983;39:761-765.
9. Block M S & Kent J N. Healing of mandibular ridge augmentation using hydroxyapatite with or without autogenous bone in dogs. *J Oral Maxillofac Surg* 1980;43:3-7.
10. Blomqvist JE, Alberius P, Isaksson S: Retrospective analysis of one-stage maxillary



sinus augmentation with endosseous implants.  
Int J Oral Maxillofac Implants 1996;11:512-521.

11. Bostrom MP, Lane JM, Berberian WS, Missri AA, Tomin E, Weiland A, Doty SB, Glaser D & Rosen VM. Immunolocalization and expression of bone morphogenetic proteins 2 and 4 in fracture healing.  
Journal of Orthopaedic Research 1995;13:357-367.
12. Braidman I P, Davenport L K, Carter H, Selby P L, Mawer E B, Freemont A J. Preliminary in situ identification of estrogen target cells in bone.  
J Bone Mineral Research 1995;10: 74-80.
13. Chang C-S, Matukas V J & Lemons J E. Histological study of hydroxyapatite as an implant material for mandibular augmentation.  
J Oral Maxillofac Surg 1983;41:729-737.
14. Cummings S R, Kelsey J L, Nevitt M C, O'Dowd K J. Epidemiology of osteoporosis and osteoporotic fractures. Epidemiol Rev 1985;7:178-208.
15. Danckwardt- Lillieström G. Reaming of the medullary cavity and its effect on diaphyseal bone. A fluorochromic, microangiographic and histological study on the rabbit tibia and dog femur. Acta orthop Scand 1969;( Suppl 128 ):1-153.
16. Dannucci G A, Martin R B, Patterson- Buckendahl P. Ovariectomy and trabecular bone remodelling in dogs. Calcif Tiss Int 1987;40:194-199.
17. Dao TTT, Anderson J D, Zarb G A. Is osteoporosis a risk factor for Osseo integration of dental implants? Int J Maxillofac Impl 1993;8:137-44.
18. Delloye C, Cnockaert N, Cornu O. Bone substitutes in 2003: An overview  
Acta Orthopaedica Belgica 2003;69:1-8.
19. Donath K. Die Trenn-Dunnschliff- Technik zur Herstellung histologischer Präparaten von nicht sneidbaren gewebe und materialen.  
Der präparator 1988;34:197-206.

20. Drobeck H P , Rothstein S S, Gumaer K I, Sherer A D & Slighter R G.  
Histological observation of soft tissue responses to implanted multifaceted particles and discs of hydroxyapatite.  
J Oral Maxillofac Surg 1984;42:143-149.
21. Edwards J-T, Diegmann M-H, Scarborough N-L.  
Osteoinduction of human demineralized bone: characterization in a rat model.  
Clin-Orthop. 1998;357:219-28.
22. Enneking W F, Morris J L. Human autologous cortical bone transplants.  
Clin Orthop 1972;87:28-32.
23. Evans MJ, Livesey JH, Ellis MJ, Yandle TG. Effect of anticoagulants and storage temperatures on stability of plasma and serum hormones. Clin Biochem 2001;34:107-112.
24. Finn R A, Bell W H, Brammer J A. Interpositional "grafting" with autogenous bone and coralline hydroxyapatite.  
J Oral Maxillofac Surg 1980;8:161-256.
25. Glaser DL, Kaplan FS. Osteoporosis. Definition and clinical presentation.  
SPINE 1997;22:125-165.
26. Glowacki J,Mulliken JB,Kaban LB,Folkman J,Murray JE.  
Use of demineralised allogeneic bone implants for the correction of maxillocraniofacial deformities.  
Ann-Surg. 1981:Sep 194(3):366-372.
27. Glowacki J,Upton J, Boyajian M, Mulliken JB. The use of demineralised xenogeneic bone implants to correct phalange defects: a case report.  
J Hand-Surg. 1984;9(3):388-391.
28. Goulding A, Fischer L. Preventive effects of clomiphene citrate on estrogen deficiency osteopenia elicited by LHRH agonist administration in the rat. J Bone Mineral Res 1991;11:1177-1181.

29. Griffin MG, Kimble R, Hopfer W, Pacifici R. Dual-energy X-ray absorptiometry of the rat: Accuracy, precision and measurement of bone loss. *Journal of Bone and Mineral Research* 1993;8:795-800.
30. Groeneveld E H J and Burger E H. Bone morphogenetic proteins in human bone regeneration. *European Journal of Endocrinology* 2000;142: 9–21.
31. Habets LL, Bras J, Borgmeyer-Hoelen AM. Mandibular atrophy and metabolic bone loss. *Endocrinology, radiology and histomorphometry. Int-J-Oral-Maxillofac-Surg.* 1988;17:208-211.
32. Hallman M, Cederlund A, Lindskog S, Lundgren S, Sennerby L. A clinical histological study of bovine hydroxyapatite in combination with autogenous bone and fibrin glue for maxillary sinus floor augmentation. Results after 6-8 months of healing. *Clinical Oral Implants Research* 2001;2:135-143.
33. Holmes R E, Hagler K H. Porous hydroxyapatite as a bone graft substitute in cranial reconstruction: a histometric study. *J Plast Reconstr Surg* 1988;81:661-71.
34. Isaksson S. Aspects of bone healing and bone substitute incorporation. Doctoral Thesis, University of Lund, Sweden, 1992.
35. Jarcho M. Calcium phosphates ceramics as hard tissue prosthetics. *Clin Orthop* 1981;157:259-278.
36. Jarcho M, Kay J F, Gumaer K I, Doremus R H & Drobeck H P. Tissue, cellular and sub cellular events at a bone-ceramic hydroxyapatite interface. *J Bioeng* 1977;1:79-92.
37. Jarzem P, Harvey E J, Schenker R, Hajipavlou A. The effect of fibrin sealant on spinal fusion using allograft in dogs. *Spine* 1996;21:1307-1312.
38. Judd HL, Korenman SG. Effects of aging on reproductive function in woman. *Endocrine aspects of aging. Elsevier Biomedical* 1982:163-197.

39. Kania R E, Meunier A, Hamadouche M, Seidel L, Petite H. Addition of fibrin sealant to ceramic promotes bone repair: Long-term study in rabbit femoral defect model. *J Biomed Mater Res* 1998;43:38-45.
40. Katagiri T, Yamaguchi A, Ikeda T, Yoshiki S, Wozney JM, Rosen V, Wang EA, Tanaka H, Omura S & Suda T. The non-osteogenic mouse pluripotent cell line, C3H10T1/2, is induced to differentiate into osteoblastic cells by recombinant human bone morphogenetic protein-2. *Biochemical and Biophysical Research Communications* 1990;72:295–299.
41. Kay J F, Domarus R H & Jarhco M. Ion micro milling of bone implants interface. *Trans 4th Ann meet Soc Biomater 10 the Int Biomater Symp* 1978:154.
42. Kent J N, Quinn J H, Zide M F, Guerra L R, Boyne P J. Alveolar ridge augmentation using nonresorbable hydroxyapatite with or without autogenous cancellous bone. *J Oral Maxillofac Surg* 1983;41:629-42.
43. Kimmel D B, Coble T, Lane N. Long term effect of naproxen on cancellous bone in ovariectomized rats. *Bone* 1992;13:167-172.
44. Kingsley DM. The TGF-beta superfamily: new members, new receptors, and new genetic tests of function in different organisms. *Gender and Development* 1994;8:133–146.
45. Kuroda S, Mukohyama H, Kondo H, Aoki K, Ohyama T, Kasugai S. Experimental oral pathology. Bone mineral density of the mandible in ovariectomized rats: analyses using dual energy X-ray absorptiometry and peripheral quantitative computed tomography. *Oral diseases* 2003;9:24-29.
46. Kübler N, Reuther J, Kirchner T, Priessnitz B S W. Osteoinductive, morphologic and biomechanical properties of autolyzed antigen extracted allogeneic bone. *J Oral Maxillofac Surg* 1993;51:1346-1357.
47. Lane J M. Metabolic bone disease and fracture healing. In: Heppenstall RB (Ed). *Fracture treatment and healing*. Saunders, Philadelphia 1980:946-962.

48. Lane N, Coble T, Kimmel D B. Effect of naproxen on cancellous bone in Ovariectomized rats. *J Bone Min Res* 1990;5:1029-1035.
49. Lundgren S, Rosenquist J B. Short term bone healing in calcium deficiency osteopenia and disuse osteopenia; experimental studies in adult rats. *Scand J Dent Res* 1992;100:337-9.
50. Marinoni E C, Ulivi M & Bonfiglio G. The combination of fibrin sealant ( Tisseel® ) with hydroxyapatite in bone surgery. *Traumatology and Orthopaedics*. Springer Verlag 1986;7:198-201.
51. Marx R E, Miller R I, Ehler W J, Hubbard G, Malinin T I. A comparison of particulate allogeneic and particulate autogenous bone grafts into maxillary alveolar clefts in dogs. *J Oral Maxillofac Surg* 1984;42:3-9.
52. Massague J. The transforming growth factor-beta family. *Annual Review of Cell Biology* 1990;6:597-641.
53. Meredith N, Alleyne D, Cawley P. Quantative determination of the stability of the implant-tissue interface using resonance frequency analysis. *Clin Oral Implants Res* 1996;7:261-267.
54. Meredith N, Shagaldi F, Alleyne D, Sennerby I, Cawley P. The application of resonance frequency measurements to study the stability of titanium implants during healing in the rabbit tibia. *Clinical Oral Implants Research* 1997;8:234-243.
55. Mital M, Cohen J. Repair of experimental bone intramedullary injuries varying in degree. *Surgical forum* 1966;17:451-452.
56. Monaghan BA, Kaplan FS, Lyttle CR, Fallon MD, Boden SD, Haddad JG. Estrogen receptors in fracture healing. *Clin-Orthop*. 1992;280:277-280.
57. Nique T, Fonseca RJ, Upton LG. Particulate allogeneic bone grafts into maxillary alveolar clefts in humans. *J Oral Maxillofac Surg* 1987;45:386-9.

58. Nishimoto S K, Chang C H, Gendler E, Stryker W F, Nimni H E. The effect of aging on bone formation in rats: Biochemical and histological evidence for decreased bone formation capacity. *Calcif Tissue Int* 1985;37:617-24.
59. Nolan P, Templeton P, Mollan RAB, Wilson DJ. Osteoinductive potential of human demineralised bone and a bioceramic in the abdominal musculature of the rat. *J Anat* 1991;174:97-102.
60. Ogiso M, Tabata T, Lee RR, Borgese D. Delay method of implantation enhances implant-bone binding: a comparison with the conventional method. *The International Journal of Oral & Maxillofacial Implants* 1995;10:415-420.
61. Onishi T, Ishidou Y, Nagamine T, Yone K, Imamura T, Kato M, Sampath TK, ten Dijke & Sakou T. Distinct and overlapping patterns of localization of bone morphogenetic protein (BMP) family members and a BMP type II receptor during fracture healing in rats. *Bone* 1998;22:605–612.
62. Piecuch J F. Augmentation of atrophic edentulous ridge with porous replamineform hydroxyapatite (Interpore 200). *Dent Clin North Am* 1986;30:291-305.
63. Piecuch J F, Goldberg A J & Shastry C V. Compressive strength of implanted porous replamineform hydroxyapatite. *J Biomed Mater Res* 1984;18:39-45.
64. Piecuch J F, Topazian R G, Skoly S & Wolfe S. Experimental ridge augmentation with porous hydroxyapatite implants. *J Dent Res* 1983;62:148-154.
65. Reddi AH. Role of morphogenetic proteins in skeletal tissue engineering and regeneration. *Nature Biotechnology* 1998;16:247–252.
66. Reddi AH, Huggins CB. Biochemical sequences in the transformation of normal fibroblasts in adolescent rats. *Proc Natl Acad Sci* 1972;69:1601-1605.
67. Reddi AH, Wientroub S & Muthukumaran N. Biologic principles of bone induction.

Orthopaedic Clinics of North America 1987;18:207–212.

68. Revell P A. Histomorphometry of bone, J Clin Pathol 1983;36:1323-31.
69. Riggs BL, Melton LJ. Involutional osteoporosis.  
N Engl J Med 1986;314:1676 -1677.
70. Riggs BL, Wahner HW, Melton LJ, Richelson LS, Judd HL, Offord KP. Rates of bone loss in appendicular and axial skeletons of women. J Clin Invest 1986;77:1487-1497.
71. Ripamonti U. Calvarial regeneration in primates with autolyzed antigen extracted allogeneic bone. Clin Orthop 1992;282:293-303.
72. Ripamonti U, Schnitzler C M, Cleaton-Jones P C. Bone induction in a composite allogeneic bone/ alloplastic implant.  
J Oral Maxillofac Surg 1989;47:963-969
73. Roberts EW, Garetto LP, Chen J, Parr JA. Remodeling dynamics of bone supporting rigidly fixed titanium implants: a histomorphometric comparison in four species including humans. Implant-Dent. 1995;4(4):235-243.
74. Roberts EW, Smith RK, Zilberman Y, Mozsary PG, Smith RS.  
Osseous adaptation to continuous loading of rigid endosseous implants.  
Am J Orthod 1984;86:95.
75. Rooney T, Berman S, Indresano A T. Evaluation of porous block hydroxyapatite for augmentation of alveolar ridges.  
J Oral Maxillofac Surg 1988;46:15-18.
76. Rosen DM, Bentz H, Nathan RM ,Armstrong RM, Thompson AY, Segarini PR, Mathews MC, Dasch JR, Piez KA, Seyedin SM. Purification and characterization of a unique osteoinductive factor from bovine bone.  
J Biol-Chem. 1989;5:264(34):20805-10.
77. Rosenquist J B, Lundgren S. Sensitivity to low calcium diet in different

- bones; an experimental study in adult rats.  
Scand J Dent Res 1992;100:327-330
78. Rosenquist J B, Rosenquist K, Sund G. Effects of bone grafting on maxillary bone healing in the growing pig.  
J Oral Maxillofac Surg 1982;40:566-9.
  79. Sailer H F, Kolb E. Application of purified bone morphogenetic protein (BMP) in cranio-maxillo- facial surgery.  
J Cranio-Maxillo-Facial Surgery 1994;22:2-11.
  80. Sampath TK & Reddi AH. Homology of bone-inductive proteins from human, monkey, bovine, and rat extra cellular matrix.  
Proceedings of the National Academy of Sciences of the USA 1983: 80: 6591–6595.
  81. Schenk R, Buser D, Hardwick R, Dahlin C. Healing pattern of bone regeneration in membrane-protected defects. A histological study in canine mandible.  
J Oral Maxillofac Impl 1994;9:13- 29.
  82. Schmitz JP, Hollinger JO, Milam SB. Reconstruction of bone using calcium phosphate bone cements: A critical review.  
J Oral Maxillofac Surg. 1999;57:1122-1126.
  83. Sennerby L, Thomsen P, Ericson LE. Early tissue response to titanium implants inserted in rabbit cortical bone. Part I. Light microscopic observations. Journal of Materials Science. Materials in Medicine 1993;4:240-250.
  84. Slotte C, Lundgren D, Sennerby L, Lundgren AK. Influence of preimplant surgical intervention and implant placement on bone wound healing: A rabbit jawbone study. Clinical Oral Implants Research 2003, in press.
  85. Turgut M, Erkus M, Tavus N. The effect of fibrin adhesive ( Tisseel ) on interbody allograft fusion: An experimental study with cats.  
Acta Neurochir ( Wien) 1999;141:273-278.



86. Uchida A, Nade S, McCartney E & Ching W. Bone in growth into three different porous ceramics implanted into the tibia of rats and rabbits. *J Orthop Res* 1985;3:65-77.
87. Urist M R, Mikulski A, Boyd S D. A chemo sterilized antigen-extracted auto digested alloimplant for the bone banks. *Arch Surg* 1975;110: 53-101.
88. Urist MR. Bone formation for autoinduction. *Science* 1965;150:893-899
89. Urist MR. Bone morphogenetic protein, bone regeneration, heterotopic ossification and the bone-bone marrow consortium. In: Peck W A (ed): *Bone and Mineral Research*(ed 6), Amsterdam, The Netherlands, Elsevier Science. 1989: pp 57-112.
89. Urist MR, Nilsson O, Rasmussen J, Hirota W, Lowell T, Schalzreid T, Fineman G A M. Bone regeneration under the influence of a bone morphogenetic protein (BMP) beta tricalcium phosphate (TCP) composite in skull trephine defects in dogs. *Clin Orthop* 1987;214:295-304.
91. Van de Putte KA & Urist MR. Osteogenesis in the interior of intramuscularly implants of decalcified bone matrix. *Clinical Orthopaedics and Related Research* 1965: 257–270.
92. Wang EA. Bone morphogenetic proteins (BMPs): therapeutic potential in healing bony defects. *Trends In Biotechnology* 1993;11: 379–383.
93. Wang X, Baolin L, Yan J, Xi Y. The effect of bone morphogenetic protein on osseointegration of titanium implants. *J Oral Maxillofac Surg* 1993;51:647-651.
94. Wolford L M, Wardrop R W, Hartog J M. Coralline porous hydroxyapatite as a bone graft substitute in orthognatic surgery. *J Oral Maxillofac Surg* 1987;45:1034-42.
95. World Health Organization Study Group. Assessment of fracture risk and its application to screening for postmenopausal osteoporosis.

World Health Organ Tech Rep Ser 1994:843:1-129.

96. Öberg S, Rosenquist JB. Bone healing after implantation of hydroxyapatite granules and blocks ( Interpore 200®9 combined with autolyzed antigen-extracted allogeneic bone fibrin glue. Experimental studies on adult rabbits.  
Int. J. Oral Maxillofac. Surg. 1994;23:110-114.
97. Öberg S, Kahnberg K-E. Combined use of hydroxyapatite and Tisseel® in experimental bone defects in the rabbit. Swed Dent J 1993: 7:147-153.
98. Öberg S, Rosenquist JB, Johansson C. Bone formation after implantation of autolyzed antigen-extracted allogeneic bone in ovariectomized rabbits.  
Int. J. Oral Maxillofac. Surg. 2003; 32 :00-00.  
doi:10.1054/ijoms.2002.0428.