



Dentoskeletal and soft tissue changes after treatment of crowding with premolar extractions: a 50-year follow-up

Nameer Al-Taai¹, Maurits Persson¹, Maria Ransjö^{1,2}, Eva Levring Jäghagen³ and Anna Westerlund²

¹Orthodontics, Department of Odontology, Umeå University, Umeå, Sweden

²Department of Orthodontics, Sahlgrenska Academy, University of Gothenburg, Gothenburg, Sweden

³Oral and Maxillofacial Radiology, Department of Odontology, Umeå University, Umeå, Sweden

Correspondence to: Nameer Al-Taai, Department of Odontology, Umeå University, SE-901 85 Umeå, Sweden. E-mail: nameer.al-taai@umu.se

Summary

Background: The long-term effects on dentofacial morphology of interceptive treatment with premolar extractions, in the absence of subsequent orthodontic treatment, have not been fully explored.

Objective: The aim was to investigate the effects of premolar extractions (without subsequent orthodontic treatment) on the dentoskeletal and soft tissue profile of patients aged between 12 and 62 years with Class I malocclusion with severe crowding, as compared to untreated controls.

Materials and methods: The Extraction group ($N = 30$ with Class I crowding malocclusion) had their first premolars removed in early adolescence without subsequent orthodontic treatment. The Control group included 30 untreated subjects with Class I normal occlusion. Cephalograms were taken at 12 (T1), 15 (T2), 30 (T3), and 62 (T4) years of age. A superimposition-based cephalometric method was used to assess the dentoskeletal and soft tissue changes.

Results: There were no significant differences between the Extraction and Control groups in terms of skeletal sagittal relation, incisor inclination, and protrusion, or most of the soft tissue parameters throughout the observation period. However, significant differences were observed between the groups with respect to the vertical relations in T2–T3, such that the Extraction group showed more-pronounced decreases in the ML/NSL, ML/NL, and Gonial angles and more-pronounced increases in facial heights.

Conclusions and implications: Treatment for subjects with Class I malocclusion with severe crowding by the extraction of four premolars, without subsequent orthodontic treatment, does not affect the long-term dentoskeletal and soft tissue profile, as compared to an untreated Control group. The degree of crowding, rather than changes in dentofacial morphology, is crucial in deciding on extraction therapy.

Introduction

Longitudinal growth studies have reported significant, age-related, craniofacial changes during adulthood (1–3). Interest in facial aesthetics has increased markedly in recent years. Cosmetic treatments, such as Botox and filler injections, are frequently used to counteract age-related facial changes (4). Orthodontists also have the opportunity to influence the facial profile by changing the soft tissue-supporting structures, e.g. the positions of the teeth and dental arches (5,6).

Several studies have evaluated the effects of extractions and subsequent orthodontic treatment on craniofacial changes (7–16). Some studies have reported no significant differences between the extraction and non-extraction orthodontic treatment outcomes (10,11,15,16). However, other studies have found that premolar extraction can affect the dentoskeletal and soft tissue profile (7–9,12). Possible reasons for these discrepant results are differences in the study designs and inadequate control groups. Consequently, there is still no clear consensus on the effects that tooth extraction has on the dentoskeletal and soft tissue profile, despite the fact that crowding of the teeth is the most common type of malocclusion (17,18). Furthermore, continuous thinning of the lips

and changes in the vertical facial dimension are considered to be normal, age-related physiological changes (2,3).

As a consequence of the current aesthetic ideal, whereby patients favour fuller lips, non-extraction orthodontic treatment options have become more popular. The potential changes in lip position following premolar extraction and incisor retraction (7,8) may jeopardize the aesthetics. As a result, orthodontists are reluctant to choose extraction treatment to relief crowding. Furthermore, the tendency to treat teeth crowding without extraction has been amplified by the marketing of clear aligners and new bracket systems. This is the situation despite the fact that many cases should have been treated with extraction to achieve optimal outcomes.

It can be argued that orthodontic treatment, following premolar extraction, may counteract adverse effects of the extraction on the soft tissue profile and vertical dimension. It is, therefore, interesting to study the long-term effects on dentofacial structures of premolar extraction without subsequent orthodontic treatment. To date, only one study has investigated the effect of serial extraction, without subsequent orthodontic treatment, on the soft tissue profile of patients aged up to 20 years (14).

The aim of present study was to investigate the effects of premolar extractions, without subsequent orthodontic treatment, on the dentoskeletal and soft tissue changes in a group of patients with Class I malocclusion with severe crowding (Extraction group), from early adolescence to late adulthood, compared with a matched control group of orthodontically untreated subjects with Class I normal occlusion (Control group).

Materials and methods

Design

The study was approved by the Regional Ethical Board in Umeå, Sweden (registration no. 2012-410-31M). Written informed consent was obtained from all participants at 60 years of age. The present study is a longitudinal study, in which follow-ups are performed from early adolescence (12 years; T1) to late adolescence (15 years; T2) to early adulthood (30 years; T3) and to late adulthood (62 years; T4).

Lateral cephalograms were taken for all participants on all four occasions. For the controls, all the radiographic examinations were justified for research purposes. In the Extraction group, the cephalometric examinations at T1 and T2 were justified as part of the treatment, whereas at T3 and T4 they were justified for research purposes. The radiation dose for a lateral cephalogram is approximately 5.6 μSv , which is equivalent to exposure to background radiation for 0.7 days (19). This can be compared to a low-dose cone beam computed tomography (CBCT) examination, for which the radiation dose is 15- to 26-fold higher (20).

Material

The subjects in the study, when it was established in the 1960s, were all patients in the Public Dental Health Care in Umeå, Sweden (21,22).

The material in the present study included standardized cephalograms from two groups.

Extraction group

The Extraction group consisted of 30 patients from Persson's study (21). Initially, these patients had Angle Class I crowding malocclusion, with a mean space deficiency of about 7 mm in each dental arch (without other malocclusions) at 11 years of age (T1). In addition, they were classified as having a harmonious soft tissue profile and the mean values of the overjet and overbite were 3.9 mm and 3.8 mm, respectively. The 30 patients had all their first premolars extracted at a mean age of 11.5 years, to relieve crowding, without subsequent orthodontic treatment. More information on the consequences of extraction spaces were presented in the study of Persson *et al.* (21). The 30 patients were documented with cephalograms at mean ages of 11.7 years (T1), 14.5 years (T2), and 30.5 years (T3), with three and five missing cephalograms at T1 and T2, respectively. Only subjects still living in the public dental care region were invited to participate in the study at T4. In total, 27 subjects were documented at a mean age of 62.8 years (T4), although 2 subjects were excluded due to missing first molars (Figure 1).

Control group

The Control group consisted of 30 untreated subjects from the study of Thilander *et al.* (22). At 12 years of age (T1),

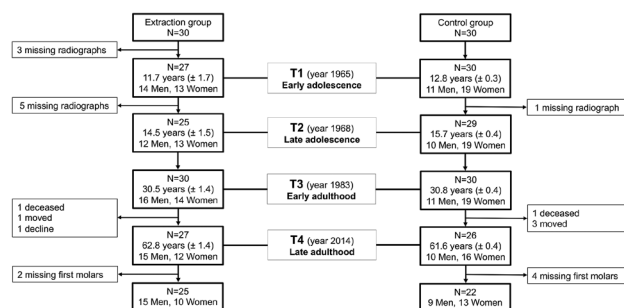


Figure 1. Flowchart of the subjects in the Extraction and Control groups, listing the sex and mean age (SD) of the participants in the study and indicating the numbers of dropouts in periods T1, T2, T3, and T4.

these subjects had normal sagittal occlusion (without any malocclusions) with mean relative spaces of about +1 mm and -1 mm in the upper and lower dental arches, respectively. In addition, they had a normal soft tissue profile (23) and the mean values of the overjet and overbite were 3 mm and 3 mm, respectively. The 30 untreated subjects were documented with cephalograms at mean ages of 12.8 years (T1), 15.7 years (T2), and 30.8 years (T3), with one missing cephalogram at T2. Only subjects still living in the public dental care region were invited to participate in the study at T4. In total, 26 subjects were documented at a mean age of 61.6 years (T4), although 4 subjects were excluded due to missing first molars (Figure 1).

The exclusion criteria were: orthodontic treatment; maxillofacial surgery; using mandibular advancement devices for treatment of snoring; craniofacial anomalies; missing teeth and prosthodontic treatment including teeth mesial to the upper and lower second molars.

Methods

For both groups, the lateral cephalograms were analogue radiographs, exposed using the same cephalostat, the Philips Super Rotalix x-ray tube (Philips, Germany), at T1, T2, and T3 with magnification factor of 1.1 (in the midline). The cephalograms at T4 were digital radiographs, acquired using the Cranex cephalostat (Soredex, Helsinki, Finland), also with magnification factor of 1.1 (in the midline). Linear measurements were adjusted to a standardized enlargement of 10% (24).

All the cephalograms were acquired with habitual occlusion and with relaxed lips. To conduct the digital cephalometric analysis, all the cephalograms from T1, T2, and T3 were scanned with the Epson Perfection V750 Pro digital scanner (EPSON Europe B.V.) at a resolution of 250 dpi. Thereafter, the cephalograms were imported as JPEG files into the FACAD® ver. 3.9.2.1133 cephalometric software. To enable calibration of the linear measurements in both groups, a calibration ruler was placed on each radiograph during scanning at T1, T2, and T3, and the cephalostat used at T4 was equipped with a calibration ruler. All the cephalograms were coded in FACAD, so as to perform randomized tracing.

Cephalometric analysis

In all, 26 cephalometric landmarks and 6 lines were used in the present study (Figure 2), and 42 angular and linear cephalometric parameters were used to describe the dental,

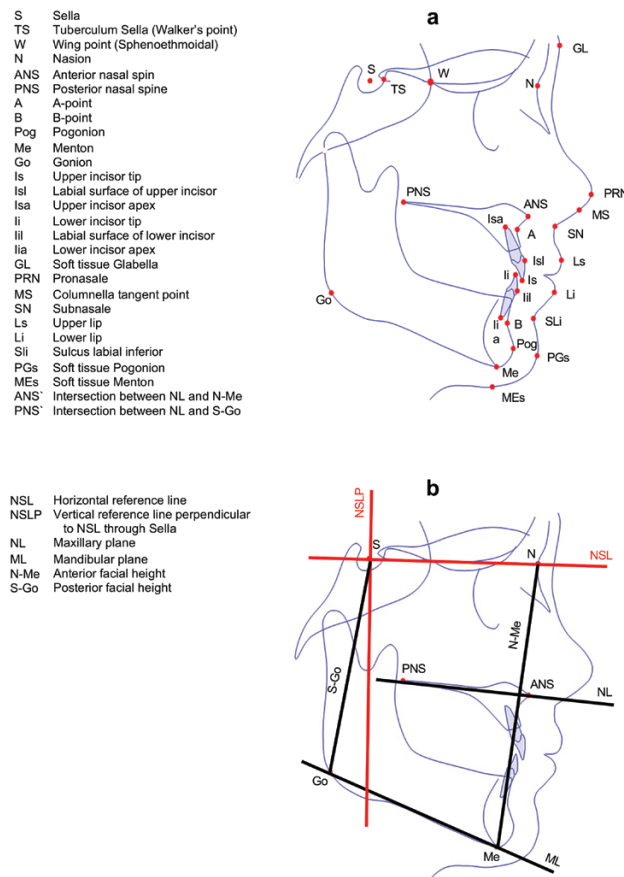


Figure 2. (a) Cephalometric landmarks. (b) Lines used in the present study.

skeletal, and soft tissue morphologies (Supplementary Table). Two reference lines, the nasion-sella line (NSL) and a perpendicular line through the sella (NSLP), and two reference landmarks, sella (S) and nasion (N), were used in the T1 cephalogram.

A superimposition-based cephalometric method (25) was used to measure 22 of 42 parameters at T2, T3, and T4 in relation to the S and N landmarks at T1. Superimposition was performed on the anterior cranial base using the Tuberculum Sella-Wing point method (25). After superimposition, reference lines NSL and NSLP and landmarks S and N were transferred digitally from the T1 cephalogram to the T2, T3, and T4 cephalograms. The FACAD program enabled measurements of the 22 parameters for each of the T2, T3, and T4 cephalograms in relation to these transferred reference lines and landmarks from the T1 cephalogram.

A conventional cephalometric method was used to perform direct measurements (independent of the superimposition) of the remaining 20 parameters. The cephalometric analysis and superimposition, for all included subjects, were performed digitally by one orthodontist (NA-T).

Similarities between the Extraction and Control groups in terms of dentoskeletal and soft tissue morphologies at T1 were required to exclude the influences of confounding factors on the studied parameters. Therefore, a comparison of 15 parameters, describing the dentoskeletal and soft tissue patterns, was performed for the groups at baseline (T1) (Table 1).

The changes in 42 parameters, from T1 to T2, T2 to T3, and T3 to T4 in the Extraction group, were compared with the corresponding changes in the Control group (Tables 2–4).

Error of method

In order to evaluate the intra-observer reliability of the cephalometric measurements, 20 randomly selected cephalograms were retraced by the same orthodontist (NA-T) 3 months after the initial tracing. The intra-observer reliability was assessed by estimating the intra-class correlation coefficients (ICCs) with 95% confidence intervals. The intra-observer reliability of the cephalometric measurements was good, with ICCs in the range of 0.92–0.99 for most of the parameters. However, the ICCs were 0.84 and 0.88 for the horizontal distance of menton to vertical reference line (Me-NSLP) and nasolabial angle, respectively. The inter-observer reliability of the cephalometric measurements has been described by Al-Taai et al. (3).

Statistical analysis

Independent samples *t*-test were used to determine significant differences in the skeletal, dental, and soft tissue patterns between the Extraction and Control groups at baseline (T1).

Tests of differences in changes to the dentoskeletal and soft tissues between the Extraction and Control groups were carried out using the independent samples *t*-test.

To maximize the use of available information in data, the analyses of differences between time points have been performed using a pairwise deletion approach rather than listwise deletion. Thus, if a subject had measurements allowing the calculation of a change between two time points, this data point contributed to the analyses regardless if data were missing at some other time points for that subject.

All statistical analyses were performed using the R ver. 4.0.0 software (R Core Team 2020), and the significance level was set at $P < 0.05$.

Results

Cephalometric comparisons at baseline (T1) between the Extraction and Control groups showed no significant differences for the skeletal sagittal and vertical relations, incisor inclination, and soft tissue profile (Table 1). Although significant differences were found between the two groups in the SNB, ANB, and facial profile angles, the values were within the normal range of orthognathic morphology (3).

Tables 2–4 show the mean differences in the skeletal, dental, and soft tissue changes, respectively, between the time points for the Extraction and Control groups, and present the tests of differences in the changes between the groups at the different periods.

Changes from T1 to T2

During the adolescence period, no significant differences in dentoskeletal and soft tissue changes were found between the groups, with two exceptions. The distance between the lower incisor and A-Pogonion line (Ii-APog) increased 0.6 mm more in the Extraction group, and the Mentolabial angle increased in the Control group and decreased 5° in the Extraction group (Tables 2–4).

Changes from T2 to T3

From late adolescence to early adulthood, the changes in the sagittal position of the maxilla (SNA) and chin (SNPog)

Table 1. Mean values (SD) for the dental, skeletal and soft tissue parameters, comparing the Extraction and Control groups at baseline (T1).

Time point/parameters	Extraction group (N = 27) T1	Control group (N = 30) T1	Test of differences between groups (P-value)
Sagittal relations			
SNA (°)	81.86 (3.51)	82.52 (3.16)	0.460
SNB (°)	79.09 (3.49)	80.75 (2.47)	0.041
ANB (°)	2.79 (1.72)	1.78 (1.57)	0.024
Vertical relations			
ML/NSL (°)	33.56 (4.95)	31.85 (4.45)	0.176
NL/NSL (°)	6.21 (3.60)	6.00 (2.65)	0.800
ML/NL (°)	27.35 (4.73)	25.84 (4.55)	0.224
Dental relations			
ILs/NL (°)	109.87 (6.48)	111.81 (4.44)	0.191
ILi/ML (°)	87.06 (5.92)	88.33 (4.69)	0.371
Interincisal angle (°)	135.72 (9.77)	134.02 (7.20)	0.455
Soft tissue profile			
Total facial convexity (°)	142.80 (4.82)	144.22 (3.91)	0.227
Facial profile angle (°)	166.06 (5.17)	168.95 (3.51)	0.016
Nasolabial angle (°)	115.39 (10.99)	112.00 (8.61)	0.197
Mentolabial angle (°)	134.96 (9.74)	136.07 (7.78)	0.634
Upper lip thickness (mm)	11.98 (1.69)	11.99 (1.48)	0.983
Lower lip thickness (mm)	13.30 (1.59)	12.63 (1.06)	0.066

Bold entries highlight the statistically significant value.

showed significantly more-pronounced (1°) forward growth in the Extraction group than in the Control group. Apart from this, there were no significant differences in skeletal sagittal changes between the groups.

Significant differences were observed between the groups for changes in the skeletal vertical parameters. The mandibular inclination (ML/NSL), vertical jaw relation (ML/NL), and Gonial angle decreased to greater extents (1.7°, 1.6°, and 2.2°, respectively) in the Extraction group. Moreover, the anterior, lower anterior, posterior, and lower posterior facial heights increased to greater extents (2 mm, 1.5 mm, 3.8 mm, and 2.8 mm, respectively) in the Extraction group.

No statistically significant differences were found between the groups in terms of changes to the incisor inclination.

Four of the twelve soft tissue profile parameters showed significant differences between the groups. The anterior (MEs-NSL) and lower anterior (NL-MEs) soft tissue facial heights increased more, by 3 mm and 2 mm, respectively, in the Extraction group. Furthermore, the protrusions of the upper and lower lips in relation to the vertical reference line (Ls-NSLP and Li-NSLP) increased in the Extraction group (Tables 2–4).

Changes from T3 to T4

From early to late adulthood, the groups exhibited no significant differences in 39 of the 42 parameters. The skeletal vertical parameters, ML/NSL and ML/NL angles, increased more in the Control group, and the distance from the upper lip to the aesthetic line (Ls-EL) increased more in the Extraction group (Tables 2–4).

Discussion

The current study shows that early extraction of four premolars as treatment for patients with Class I malocclusion

with severe crowding has no effect on the long-term changes of the dentoskeletal and soft tissue profile, as compared with an untreated control group classified as having normal occlusal and dentofacial relations.

In the present study, a long-term (up to the sixth decade of life) assessment of dentoskeletal and soft tissue changes related to the extraction of premolars, without subsequent orthodontic treatments, was performed. Given that the Extraction and Control groups showed similar dentoskeletal and soft tissue morphologies at baseline, the groups were considered to be well-matched. Thus, potentially confounding effects related to sample selection, orthodontic treatment, and/or growth were avoided in this study.

As previously reported (21), the residual extraction spaces closed in almost all the cases already at T3, and this closure was rapid initially and achieved by tipping of the adjacent teeth in the lower arch. Spontaneous alignment and space closure in Class I crowding cases, following the extraction of four premolars, may be part of a so-called ‘serial extraction treatment’. To date, only one study has investigated the effect of serial extractions, without subsequent orthodontic treatment, on the soft tissue profile from 13 to 24 years of age (14). In the 10-year follow-up (14), the serial extraction group was compared with patients who underwent serial extraction and orthodontic treatment and other patients who underwent late premolar extraction and orthodontic treatment. No significant differences were found in relation to the changes in the soft tissue profile between these three different treatment methods (14). However, that study did not include an untreated control group, and the follow-up period was shorter (14), making comparison with the present study difficult. This means that with the present study we add 40 years of knowledge to this topic.

In the present study, the groups showed similar changes in the skeletal sagittal relations throughout the observation

Table 2. Differences in the mean values (SD) of the skeletal changes between time points for the Extraction and Control groups, together with tests of the differences in the changes between the groups at different periods.

Periods/parameters	Extraction group			Control group			Test of differences between groups		
	T1-T2 (N = 25)	T2-T3 (N = 25)	T3-T4 (N = 25)	T1-T2 (N = 29)	T2-T3 (N = 29)	T3-T4 (N = 22)	P-value T1 versus T2	P-value T2 versus T3	P-value T3 versus T4
Sagittal relations									
SNA (°)*	2.17 (1.90)	1.63 (2.33)	-0.86 (1.22)	2.33 (2.04)	0.49 (1.75)	-0.97 (1.52)	0.759	0.046	0.795
SNB (°)*	1.37 (1.85)	1.03 (1.95)	-0.94 (1.30)	1.36 (1.56)	-0.05 (2.04)	-1.16 (1.27)	0.978	0.054	0.569
ANB (°)*	0.78 (1.21)	0.60 (1.45)	0.08 (0.81)	0.95 (1.07)	0.57 (1.03)	0.16 (0.82)	0.581	0.927	0.726
SNPog (°)*	1.69 (1.99)	1.26 (1.99)	-0.82 (1.47)	1.40 (1.58)	0.09 (2.08)	-1.16 (1.25)	0.551	0.039	0.397
A-NSLP (mm)*	1.51 (1.83)	1.34 (2.31)	-0.89 (1.37)	1.82 (1.88)	0.31 (1.81)	-0.96 (1.56)	0.545	0.074	0.876
B-NSLP (mm)*	1.11 (2.87)	0.97 (3.09)	-1.44 (2.39)	1.33 (2.43)	-0.42 (3.40)	-1.90 (2.22)	0.759	0.125	0.496
Pog-NSLP (mm)*	1.80 (3.34)	1.49 (3.59)	-1.50 (3.04)	1.68 (2.80)	-0.16 (3.96)	-2.15 (2.50)	0.889	0.117	0.432
Me-NSLP (mm)*	1.37 (3.57)	1.22 (3.80)	-1.42 (3.36)	1.54 (2.66)	-0.35 (4.69)	-2.38 (2.59)	0.839	0.188	0.283
Vertical relations									
ML/NSL (°)*	-0.60 (2.32)	-1.34 (2.71)	1.05 (1.69)	-0.73 (1.51)	0.40 (2.30)	2.08 (1.36)	0.798	0.013	0.027
NL/NSL (°)*	0.89 (2.33)	0.30 (1.83)	1.05 (1.68)	0.64 (1.44)	0.57 (2.06)	0.31 (1.85)	0.636	0.616	0.158
ML/NL (°)	-1.31 (2.27)	-1.81 (3.01)	0.28 (1.55)	-1.37 (1.22)	-0.14 (1.75)	1.75 (1.52)	0.913	0.014	0.002
N-Me (mm)*	6.68 (3.33)	6.25 (5.07)	-0.05 (1.86)	6.02 (3.14)	4.14 (2.11)	0.23 (1.66)	0.453	0.047	0.592
ANS'-Me (mm)	3.65 (1.81)	3.99 (3.32)	-0.65 (1.44)	3.72 (1.93)	2.59 (1.74)	0.15 (1.27)	0.888	0.053	0.053
S-Go (mm)*	5.70 (2.72)	6.56 (5.25)	-1.14 (1.49)	5.43 (2.62)	2.77 (2.75)	-2.01 (1.45)	0.713	0.001	0.050
PNS'-Go (mm)	3.02 (2.45)	4.55 (3.78)	-0.87 (1.67)	3.57 (1.76)	1.75 (2.33)	-1.71 (1.54)	0.348	0.002	0.079
A-NSL (mm)*	4.15 (2.52)	3.37 (3.30)	0.18 (1.43)	3.01 (1.92)	2.18 (1.45)	-0.40 (1.67)	0.065	0.084	0.205
B-NSL (mm)*	5.59 (2.71)	4.37 (4.08)	-0.70 (1.80)	5.14 (2.32)	2.95 (1.48)	-0.26 (1.72)	0.513	0.087	0.397
Pog-NSL (mm)*	6.82 (3.27)	6.21 (5.08)	-0.37 (1.65)	5.95 (3.13)	4.01 (2.07)	-0.55 (1.89)	0.326	0.037	0.726
Me-NSL (mm)*	7.20 (3.27)	6.54 (5.38)	-0.33 (1.57)	6.42 (3.38)	4.03 (2.11)	-0.20 (1.44)	0.400	0.024	0.774
Ar/Go/Me (°)	-2.03 (1.96)	-3.62 (2.48)	0.85 (1.53)	-2.20 (1.67)	-1.35 (2.27)	1.18 (2.34)	0.724	<0.001	0.566

Bold entries highlight the statistically significant value.

*Measured according to superimposition-based cephalometric method (25).

Table 3. Differences in the mean values (SD) of the dental relation changes between time points for the Extraction and Control groups, together with tests of the differences in the changes between the groups at different periods.

Periods/parameters	Extraction group			Control group			Test of differences between groups			
	T1-T2 (N = 25)	T2-T3 (N = 25)	T3-T4 (N = 25)	T1-T2 (N = 29)	T2-T3 (N = 29)	T3-T4 (N = 22)	P-value T1 versus T2	P-value T2 versus T3	P-value T3 versus T4	
Isa-Is/NL (°)	-1.30 (3.17)	-1.34 (3.53)	-2.24 (3.38)	-0.66 (2.72)	-0.89 (3.35)	-3.56 (3.15)	0.425	0.630	0.177	
Iia-Ii/ML (°)	-0.54 (3.86)	2.02 (4.64)	-1.58 (3.45)	0.75 (2.23)	0.91 (3.45)	-2.08 (2.53)	0.132	0.319	0.577	
Isa-Is/Iia-Ii (°)	3.18 (4.84)	1.11 (7.06)	3.53 (5.10)	1.26 (3.28)	0.14 (4.57)	3.88 (3.94)	0.089	0.547	0.793	
Isl-NSLP (mm)*	1.24 (2.08)	1.31 (2.71)	-1.08 (1.64)	1.65 (1.96)	0.12 (2.08)	-1.13 (1.79)	0.453	0.075	0.912	
Iil-NSLP (mm)*	0.96 (2.43)	1.15 (2.81)	-1.21 (2.21)	1.49 (2.08)	-0.20 (2.85)	-1.56 (2.14)	0.395	0.086	0.588	
Ii-APog (mm)	-0.81 (0.64)	-0.09 (1.17)	-0.24 (0.78)	-0.18 (0.61)	-0.13 (0.68)	-0.14 (0.72)	<0.001	0.880	0.641	
Is-NL (mm)	1.54 (1.35)	1.30 (1.70)	-0.26 (1.38)	1.29 (0.77)	1.12 (1.17)	0.14 (1.32)	0.397	0.657	0.310	
Ii-ML (mm)	1.72 (1.14)	1.88 (1.82)	-0.03 (1.00)	1.99 (1.21)	1.15 (1.16)	-0.09 (1.02)	0.399	0.078	0.843	

Bold entries highlight the statistically significant value.

*Measured according to superimposition-based cephalometric method (25).

period. Similar results have been obtained in short-term studies of orthodontically treated patients (26,27). However, the significant differences noted in the present study between the two groups with respect to the changes in the SNA and SNPog angles, from late adolescence to early adulthood, indicate slightly more anteriorly directed growth of the maxilla and chin in the Extraction group. We consider that this difference is not a result of the premolar extractions. Thus, in clinical terms, premolar extractions in cases of Class I malocclusion with severe crowding, without subsequent orthodontic treatment, do not affect the skeletal sagittal growth pattern.

It has been reported that changes in the inclination of the upper and lower incisors induced by orthodontic treatment may result in positional changes of the A and B landmarks, which in turn result in a change to the sagittal jaw relation (ANB) (28,29). It is noteworthy that throughout the entire observation period, we found no significant differences between the groups for the eight studied parameters that describe the inclination and protrusion of the incisors. The incisor retroclination observed in the Extraction group throughout the observation period was similar to that in the Control group and can be attributed to age-related changes. Moreover, incisor relations expressed by overjet and overbite exhibited no significant differences between the groups throughout the observation period (30). Therefore, in the clinical context, premolar extractions in patients with Class I malocclusion with severe crowding, without subsequent orthodontic treatment, do not affect the inclination and protrusion of the upper and lower incisors. This is in contrast to the results obtained in short-term studies, showing greater retroclination of the incisors in orthodontically treated patients with extractions, as compared to non-extraction treatments (9,26,27).

The groups showed similar skeletal vertical changes during the adolescence period. This accords with the results of short-term studies that compared the effects of orthodontic treatment with and without extractions (15,16,27). Therefore, the concept that premolar extraction, without subsequent orthodontic treatment, affects facial heights or vertical jaw relations is based on a low level of evidence, at least during adolescence.

However, from late adolescence to early adulthood, the skeletal facial heights (anterior, lower anterior, posterior, and lower posterior) increased to greater extents in the Extraction group than in the Control group. This might be explained by tipping and extrusion of the posterior teeth concomitant with mesial migration, following premolar extraction, as observed earlier (21).

In contrast to the similar changes observed for the maxillary inclination (NL/NSL) in the two groups throughout the observation period, the changes in mandibular inclination (ML/NSL) differed significantly between the groups from late adolescence to early adulthood and from early to late adulthood.

The extraction group exhibited a slight anterior mandibular rotation and slightly greater degree of deepening of the vertical jaw relation (ML/NL) and Gonial angle, as compared to the Control group, from late adolescence to early adulthood. This is attributed to the larger increase in the posterior facial height, about 4 mm, following premolar extraction.

From early to late adulthood, the Extraction group showed lower degrees of posterior mandibular rotation (1°) and

Table 4. Differences in the mean values (SD) of the soft tissue profile changes between time points for the Extraction and Control groups, together with tests of the differences in the changes between the groups at different periods.

Periods/parameters	Extraction group			Control group			Test of differences between groups			
	T1-T2 (N = 25)	T2-T3 (N = 25)	T3-T4 (N = 25)	T1-T2 (N = 29)	T2-T3 (N = 29)	T3-T4 (N = 22)	P-value T1 versus T2	P-value T2 versus T3	P-value T3 versus T4	
GL/PRN/PGs (°)	-2.26 (2.63)	-0.84 (3.10)	0.67 (2.51)	-1.41 (3.26)	-0.71 (2.91)	0.37 (2.14)	0.301	0.871	0.664	
GL/SN/PGs (°)	0.24 (2.37)	1.96 (3.26)	5.13 (3.14)	0.08 (2.34)	2.39 (2.80)	4.07 (2.49)	0.803	0.608	0.209	
MEs-NSL (mm)*	7.99 (3.46)	7.35 (6.53)	0.63 (2.23)	6.83 (3.57)	4.03 (2.43)	0.93 (1.78)	0.235	0.014	0.617	
NL-MEs (mm)	4.48 (2.25)	4.86 (4.49)	0.08 (2.08)	4.18 (2.18)	2.65 (2.12)	1.11 (1.77)	0.621	0.021	0.075	
MS/SN/Ls (°)	-0.64 (7.85)	-2.01 (6.73)	-3.42 (8.30)	0.38 (5.65)	-2.10 (7.27)	-5.49 (6.82)	0.583	0.962	0.359	
Li/Sli/PGs (°)	-5.18 (6.41)	7.48 (9.04)	3.74 (9.03)	0.40 (6.48)	4.51 (6.02)	6.18 (9.58)	0.003	0.156	0.373	
Ls-EL (mm)	-1.77 (1.24)	-2.75 (1.91)	-1.86 (1.32)	-1.52 (1.53)	-2.61 (1.54)	-0.71 (1.95)	0.509	0.759	0.022	
Li-EL (mm)	-1.29 (1.29)	-2.14 (1.73)	-1.88 (1.43)	-0.98 (1.29)	-1.81 (1.58)	-1.37 (1.43)	0.379	0.468	0.223	
Isl-Ls (mm)	1.10 (1.27)	-0.74 (1.76)	-1.61 (1.24)	0.73 (1.54)	-1.46 (1.41)	-0.92 (1.80)	0.351	0.102	0.130	
Iil-Li (mm)	1.12 (1.16)	0.28 (1.68)	-0.68 (1.36)	0.88 (1.18)	-0.16 (0.97)	-0.63 (1.34)	0.462	0.238	0.886	
Ls-NSLP (mm)*	2.41 (2.74)	0.37 (3.74)	-3.55 (2.27)	2.36 (2.45)	-1.57 (2.19)	-3.00 (2.56)	0.936	0.022	0.441	
Li-NSLP (mm)*	2.00 (3.10)	1.64 (3.64)	-2.22 (2.57)	2.56 (2.62)	-0.53 (2.68)	-2.50 (2.84)	0.477	0.015	0.724	
Ls-NSL (mm)*	4.56 (3.15)	5.26 (4.43)	3.61 (2.33)	3.95 (2.10)	3.98 (2.19)	3.96 (2.68)	0.402	0.175	0.633	
Li-NSL (mm)*	5.91 (3.80)	3.75 (3.92)	0.94 (2.74)	4.27 (2.57)	3.05 (2.61)	1.20 (3.21)	0.066	0.441	0.759	

Bold entries highlight the statistically significant value.

*Measured according to superimposition-based cephalometric method (25).

opening of the ML/NL angle (1.5°), as compared to the Control group. This reflected slight differences in the changes of the anterior relative to the posterior facial heights between the groups. Given these small differences between the groups, we cannot attribute them to premolar extraction. However, from early to late adulthood, both groups showed low levels of posterior mandibular rotation and opening of the vertical jaw relation. This is due to the remodelling that occurs within the region of the angle of the mandible from early to late adulthood, as observed by Al-Taai and colleagues (3).

Clinically, the extraction of premolars in patients with Class I malocclusion with severe crowding, without subsequent orthodontic treatment, may increase the facial heights and may, simultaneously, result in slight anterior mandibular rotation and deepening of the vertical jaw relation from late adolescence to early adulthood. Thereafter, from early to late adulthood, premolar extraction results in relatively stable facial heights concomitant with slight posterior mandibular rotation and opening of the vertical jaw relationship.

Both groups showed similar changes to the soft tissue profile, with the exceptions of the changes in the Mentolabial angle and position of the upper lip during the adolescence period and from early to late adulthood, respectively. The decrease in the Mentolabial angle in the Extraction group might be due to soft tissue growth rather than the extraction itself, given that similar changes in the sagittal relations (SNB, SNPog, B-NSLP, and Pog-NSLP) and dental inclinations (Iia-Ii/ML and Iil-NSLP) were noted in the two groups. The more-retruded upper lip in relation to the aesthetic line, as seen in the Extraction group, may reflect more-pronounced thinning of the upper lip, since similar changes in the sagittal relations (SNA and A-NSLP) and dental inclination (Isa-Is/NL and Isl-NSLP) were observed in the two groups. Short-term and long-term studies have reported more-retruded lips in patients who underwent premolar extractions and orthodontic treatment (9,11,26,27).

From late adolescence to early adulthood, the Extraction group showed more-pronounced increases in the anterior and lower anterior soft tissue facial heights than did the Control group, probably due to the more-pronounced skeletal vertical growth observed in the Extraction group. In addition, the slight protrusion of the lips in the Extraction group compared to the Control group from late adolescence to early adulthood likely reflects a more anteriorly directed growth of the jaws rather than an effect of the extraction itself.

Among the soft tissue parameters that exhibited significant differences between groups, the differences were small and could, therefore, not be considered clinically significant. Consequently, the extraction of four premolars in cases of Class I malocclusion with severe crowding does not affect the long-term soft tissue profile changes, which include: the facial profile angle, total facial convexity or nasolabial angle, and lip thickness or length, as well as the lower lip distance to the aesthetic line. This is consistent with the results of a study that compared the soft tissue profile changes in serial extraction and late premolar extraction treatments from 13 to 24 years of age (14), and also with long-term follow-up studies of extractions with subsequent orthodontic treatment (11,13).

It has been reported in short-term studies that lip position can be affected by the incisor position after extraction (9,26,27). However, our study could not confirm this, since both groups showed similar changes in incisor inclination and lip position.

Clinical implications

In cases of Class I malocclusion with severe crowding, the degree of crowding, rather than future changes in soft tissue profile and incisor inclination, should be the main consideration when choosing an extraction therapy in the absence of subsequent orthodontic treatment.

Limitations

Assessment of the growth-related changes were performed on 2D radiographs rather than 3D (CBCT) images. This technique was not available 50 years ago and is questionable from the radiation protection and ethical perspectives. The radiation dose from a lateral cephalogram is low, approximately $5.6 \mu\text{Sv}$, which is equivalent to 0.7 days of average background radiation to which general population in, for example, the USA or Sweden is exposed (19). This can be compared to a low-dose CBCT examination, where the dose is 15–26 times higher (20). Therefore, the widely used 2D lateral cephalometric radiographs can be justified from the radiation protection perspective, and are still useful when long-term assessment of craniofacial changes is performed based on superimposition.

In the present study, cephalometric measurements of 22 linear and angular parameters at T2, T3, and T4 were performed using a superimposition-based method (25). Thus, the age-related positional changes in the nasion and sella landmarks were excluded when assessing parameters related to the cranial base.

In addition, the cephalograms acquired at T1, T2, and T3 needed to be scanned. The scanning process may have caused slightly reduced resolution and some blurring.

In the current study, there were more women than men in the Control group. Given the previous findings (1,2) that men and women exhibit different directions of mandibular rotation, this may have skewed the comparison with the Extraction group. However, when the groups were merged (to achieve higher power) we observed that men showed the same vertical jaw inclination as women during T1–T2 and T2–T3 in this material.

Finally, it could be argued that the pronounced increases in facial heights in the Extraction group are a consequence of more women being included in the Control group, since it has been observed (2) that men record higher values for the linear craniofacial dimensions than women. Nevertheless, when we performed a gender-based analysis, the men and women, respectively, in the Extraction group showed greater increases in the facial heights than those in the Control group.

Conclusions

Treatment for subjects with Class I malocclusion with severe crowding by the extraction of four premolars, without subsequent orthodontic treatment, does not affect, in general, the long-term changes in the skeletal relations, incisor inclination or protrusion, and lip support or soft tissue profile, as compared to untreated controls.

Therefore, in Class I malocclusion with severe crowding, the degree of crowding, rather than changes to the dentoskeletal and facial aesthetics, is the crucial factor in deciding to employ extraction therapy without subsequent orthodontic treatment.

Acknowledgements

We thank Per Liv, PhD, certified statistician for valuable support with the statistical analyses.

Funding

This study was supported financially by the Medical Faculty of Umeå University, Sweden.

Conflicts of interest

None to declare.

Data availability

The data that form the basis for this article are presented in the paper.

Supplementary material

Supplementary material is available at *European Journal of Orthodontics* online.

References

- Pecora, N.G., Baccetti, T. and McNamara, J.A., Jr. (2008) The aging craniofacial complex: a longitudinal cephalometric study from late adolescence to late adulthood. *American Journal of Orthodontics and Dentofacial Orthopedics*, 134, 496–505.
- Behrents, R.G. (1985) *Growth in the Aging Craniofacial Skeleton. Monograph 17. Craniofacial Growth Series*. Center for Human Growth and Development; University of Michigan, Ann Arbor, MI.
- Al-Taai, N., Persson, M., Ransjö, M., Levring Jäghagen, E., Fors, R. and Westerlund, A. (2022) Craniofacial changes from 13 to 62 years of age. *European Journal of Orthodontics*, XX, 1–10.
- Wise, J.B. and Greco, T. (2006) Injectable treatments for the aging face. *Facial Plastic Surgery*, 22, 140–146.
- Pancherz, H., Bjerklin, K., Lindskog-Stokland, B. and Hansen, K. (2014) Thirty-two-year follow-up study of Herbst therapy: a biometric dental cast analysis. *American Journal of Orthodontics and Dentofacial Orthopedics*, 145, 15–27.
- Masucci, C., Franchi, L., Defraia, E., Mucedero, M., Cozza, P. and Baccetti, T. (2011) Stability of rapid maxillary expansion and facemask therapy: a long-term controlled study. *American Journal of Orthodontics and Dentofacial Orthopedics*, 140, 493–500.
- Akyalçın, S., Hazar, S., Güneri, P., Gögüs, S. and Erdinç, A.M. (2007) Extraction versus non-extraction: evaluation by digital subtraction radiography. *European Journal of Orthodontics*, 29, 639–647.
- Bishara, S.E., Cummins, D.M., Jakobsen, J.R. and Zaher, A.R. (1995) Dentofacial and soft tissue changes in Class II, division 1 cases treated with and without extractions. *American Journal of Orthodontics and Dentofacial Orthopedics*, 107, 28–37.
- Kocadereli, I. (2002) Changes in soft tissue profile after orthodontic treatment with and without extractions. *American Journal of Orthodontics and Dentofacial Orthopedics*, 122, 67–72.
- Kouvelis, G., Dritsas, K., Doulis, I., Kloukos, D. and Gkantidis, N. (2018) Effect of orthodontic treatment with 4 premolar extractions compared with nonextraction treatment on the vertical dimension of the face: a systematic review. *American Journal of Orthodontics and Dentofacial Orthopedics*, 154, 175–187.
- Rathod, A.B., Araujo, E., Vaden, J.L., Behrents, R.G. and Oliver, D.R. (2015) Extraction vs no treatment: long-term facial profile changes. *American Journal of Orthodontics and Dentofacial Orthopedics*, 147, 596–603.
- Sivakumar, A. and Valiathan, A. (2008) Cephalometric assessment of dentofacial vertical changes in Class I subjects treated with and without extraction. *American Journal of Orthodontics and Dentofacial Orthopedics*, 133, 869–875.
- Stephens, C.K., Boley, J.C., Behrents, R.G., Alexander, R.G. and Buschang, P.H. (2005) Long-term profile changes in extraction and nonextraction patients. *American Journal of Orthodontics and Dentofacial Orthopedics*, 128, 450–457.
- Wilson, J.R., Little, R.M., Joondeph, D.R. and Doppel, D.M. (1999) Comparison of soft tissue profile changes in serial extraction and late premolar extraction. *The Angle Orthodontist*, 69, 165–173; discussion 73–74.
- Kocadereli, I. (1999) The effect of first premolar extraction on vertical dimension. *American Journal of Orthodontics and Dentofacial Orthopedics*, 116, 41–45.
- Staggers, J.A. (1994) Vertical changes following first premolar extractions. *American Journal of Orthodontics and Dentofacial Orthopedics*, 105, 19–24.
- Josefsson, E., Bjerklin, K. and Lindsten, R. (2010) Self-perceived orthodontic treatment need and prevalence of malocclusion in 18- and 19-year-olds in Sweden with different geographic origin. *Swedish Dental Journal*, 34, 95–106.
- Proffit, W.R., Fields, H.W., Jr. and Moray, L.J. (1998) Prevalence of malocclusion and orthodontic treatment need in the United States: estimates from the NHANES III survey. *International Journal of Adult Orthodontics and Orthognathic Surgery*, 13, 97–106.
- Ludlow, J.B., Davies-Ludlow, L.E. and White, S.C. (2008) Patient risk related to common dental radiographic examinations: the impact of 2007 International Commission on Radiological Protection recommendations regarding dose calculation. *Journal of the American Dental Association*, 139, 1237–1243.
- Signorelli, L., Patcas, R., Peltomäki, T. and Schätzle, M. (2016) Radiation dose of cone-beam computed tomography compared to conventional radiographs in orthodontics. *Journal of Orofacial Orthopedics*, 77, 9–15.
- Persson, M., Persson, E.C. and Skagius, S. (1989) Long-term spontaneous changes following removal of all first premolars in Class I cases with crowding. *European Journal of Orthodontics*, 11, 271–282.
- Thilander, B., Persson, M. and Skagius, S. (1982) Roentgencephalometric standards for the facial skeleton and soft tissue profile of Swedish children and young adults. II. Comparisons with earlier Scandinavian normative data. *Swedish Dental Journal. Supplement*, 15, 219–228.
- Proffit, W.R., Fields, H.W., Larson, B.E. and Sarver, D.M. (2019) *Contemporary Orthodontics*. Mosby Elsevier, St. Louis, MO.
- Hatton, M.E. and Grainger, R.M. (1958) Reliability of measurements from cephalograms at the Burlington Orthodontic Research Centre. *Journal of Dental Research*, 37, 853–859.
- Al-Taai, N., Levring Jäghagen, E., Persson, M., Ransjö, M. and Westerlund, A. (2021) A superimposition-based cephalometric method to quantitate craniofacial changes. *International Journal of Environmental Research and Public Health*, 18, 5260.
- Germeç, D. and Taner, T.U. (2008) Effects of extraction and nonextraction therapy with air-rotor stripping on facial esthetics in postadolescent borderline patients. *American Journal of Orthodontics and Dentofacial Orthopedics*, 133, 539–549.
- Kirschneck, C., Proff, P., Reicheneder, C. and Lippold, C. (2016) Short-term effects of systematic premolar extraction on lip profile, vertical dimension and cephalometric parameters in borderline patients for extraction therapy—a retrospective cohort study. *Clinical Oral Investigations*, 20, 865–874.
- Al-Abdwan, R., Moles, D.R. and Noar, J.H. (2009) Change of incisor inclination effects on points A and B. *The Angle Orthodontist*, 79, 462–467.
- Sun, Q., Lu, W., Zhang, Y., Peng, L., Chen, S. and Han, B. (2021) Morphological changes of the anterior alveolar bone due to retraction of anterior teeth: a retrospective study. *Head & Face Medicine*, 17, 30.
- Persson, M., Al-Taai, N., Pihlgren, K. and Westerlund, A. (2022) Early extractions of premolars reduce age-related crowding of lower incisors: 50 years of follow-up. *Clinical Oral Investigations*, 26, 4525–4535.